

VENTANA CLDN18 (43-14A) RxDx Assay Interpretation Guide for Gastric Adenocarcinoma including Gastroesophageal Junction (GEJ)

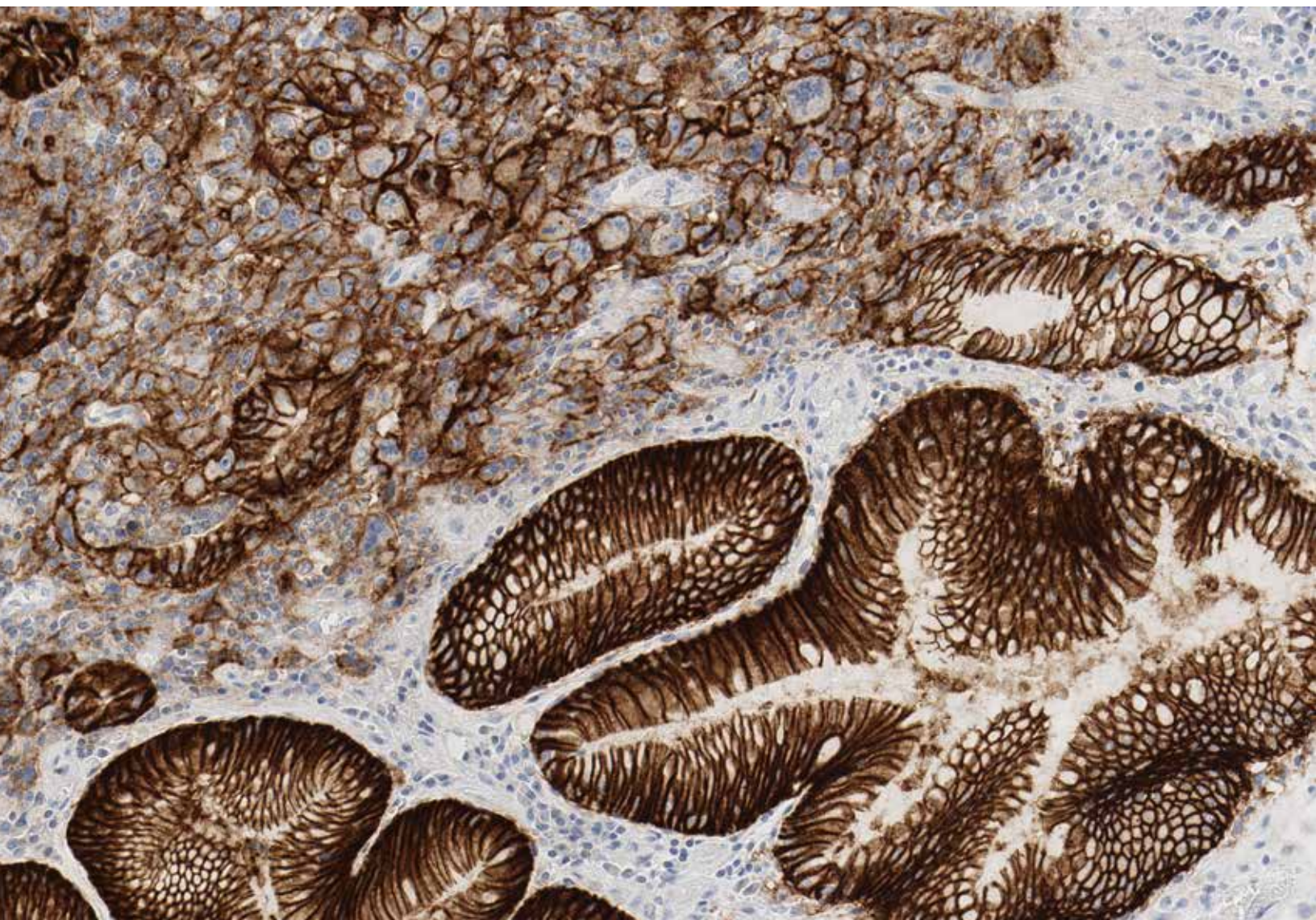


Table of Contents

Introduction	1
Intended Use	3
Intended Use of Product	3
Purpose of Interpretation Guide	3
Clinical Evaluation	4
Staining Characteristics	4
Tumor Cell Scoring	6
Morphology and Background Acceptability Criteria	7
Scoring Algorithm	8
Scoring Method	10
System Level Control	11
Specimen Flow	14
Decision Tree	15
Reference Images	16
Negative Cases	16
Borderline Cases	21
Positive Cases	27
Challenging Cases	32
Artifacts	47
Impact of Pre-Analytical Conditions on VENTANA CLDN18 (43-14A) RxDx Assay	51
Cut Slide Stability	52
References	53

Introduction

VENTANA CLDN18 (43-14A) RxDx Assay is an immunohistochemistry (IHC) assay that utilizes a mouse monoclonal antibody (clone 43-14A) to detect the transmembrane claudin 18 (CLDN18) proteins in formalin-fixed, paraffin-embedded (FFPE) gastric adenocarcinoma including gastroesophageal junction (GEJ) tissue specimens. VENTANA CLDN18 (43-14A) RxDx Assay contains a pre-dilute antibody reagent intended for use on the BenchMark instruments* with the OptiView DAB Detection Kit and VENTANA CLDN18 (43-14A) RxDx Assay Scoring Algorithm.

Gastric cancer is the fourth most common cause of cancer deaths worldwide with approximately 769,100 deaths and greater than 1 million estimated new cases in 2020.^{1,2} Almost 70% of gastric cancer diagnoses occur in developing countries, with 45.7% of all worldwide cases in Eastern Asia.³ In the US, gastric cancer is the third most common gastrointestinal malignancy after colorectal cancer and hepatocellular carcinoma. An estimated 26,380 new cases of stomach cancers and 11,090 deaths were projected in the US for 2022.⁴ Current treatment options for advanced and metastatic gastric cancer include chemotherapy, but efficacy is limited. Improvement in the clinical outcome of gastric cancer is likely to be achieved through identifying new biomarker targets and developing new treatment options.

CLDN18 belongs to the claudin protein superfamily.⁵ Claudins are tetramembrane proteins with two extracellular loops and intracellular N- and C-termini.^{5,6} Claudins are integral apical cell membrane proteins that form tight junctions, a component of cell-cell adhesion.^{5,6} Members of the claudin family play an essential role

in maintaining a permeability barrier, regulating cell migration, and conferring polarity in epithelial cells.⁵

CLDN18 is expressed as two isoforms**: CLDN18.1 and CLDN18.2. The isoforms are both 261 amino acids in length, exhibit homology in the C-terminal region but differ in the N-terminal region.^{5,6,7}

CLDN18.1 is predominantly expressed in normal and neoplastic lung tissue.^{5,6} CLDN18.2 is only expressed in differentiated epithelial cells of the gastric mucosa and not in other normal, healthy tissues.^{5,6,8} CLDN18.2 is frequently retained in gastric cancer and its metastases and may be expressed in other neoplastic tissues (e.g. pancreas, lung, ovary).^{5,6,8} Furthermore, aberrant expression of CLDN18.2 in various solid tumors (e.g. gastric, pancreatic) has been associated with loss of cell-cell adhesion, epithelial-mesenchymal transition, and tumor progression and metastasis.^{5,6} Therefore, it represents an attractive biomarker for targeted therapeutics.

**Refer to the corresponding VENTANA CLDN18 (43-14A) RxDx Assay method sheet (package insert) for the detailed intended use of this product for the appropriate BenchMark instrument(s). Please consult your local Roche representative for local approvals.*

***The primary antibody used in the VENTANA CLDN18 (43-14A) RxDx Assay targets the conserved C-terminal region of the CLDN18 proteins, and therefore cannot distinguish CLDN18.1 from CLDN18.2.*

Intended Use

Intended Use of Product

Refer to the corresponding VENTANA CLDN18 (43-14A) RxDx Assay method sheet (package insert) for the detailed intended use of this product.

Purpose of Interpretation Guide

This guide:

- Provides pathologists with a tool to facilitate or aid in the evaluation of FFPE sections of gastric adenocarcinoma tissue, including GEJ tissue, stained with the VENTANA CLDN18 (43-14A) RxDx Assay using the Assay Scoring Algorithm in accordance with the proposed product labeling.
- Provides photographic images that illustrate the staining patterns and intensities that may result from staining samples of gastric adenocarcinoma tissue, including GEJ tissue, with the Assay.
- Provides guidance in the use of gastric tissue with intestinal metaplasia tissue as a system level control (SLC) when stained with the Assay.
- Provides a reference for relating staining intensities and patterns to specific CLDN18 scores.
- Addresses challenging cases and staining artifacts.

Clinical Evaluation

Staining Characteristics

In gastric adenocarcinoma including the GEJ, neoplastic cells labeled with the VENTANA CLDN18 (43-14A) Rx Dx Assay are evaluated for percent tumor cell staining and intensity of the 3,3'-Diaminobenzidine (DAB) signal. The immunohistochemical staining in gastric cancer tissue shows the full spectrum of membrane staining from no staining to weak, moderate, and/or strong membrane staining. Cytoplasmic staining may also be present, but is not scored.

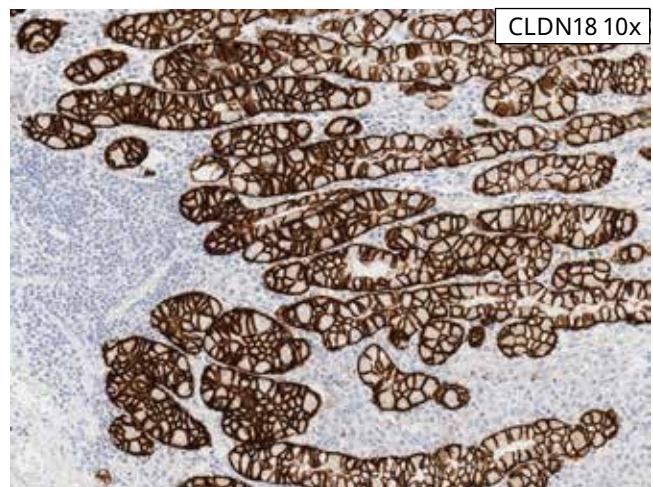
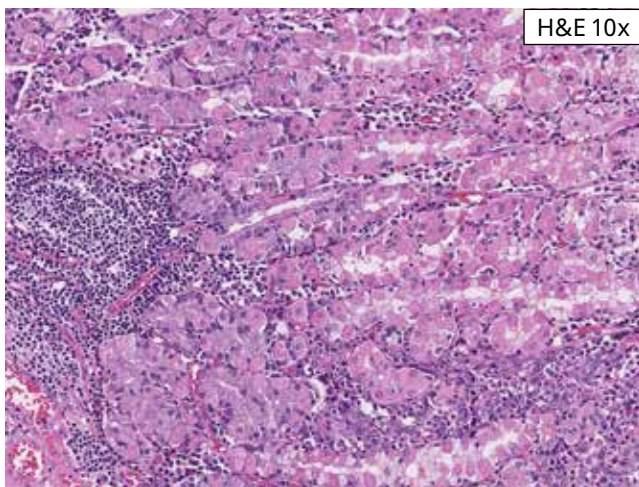
Heterogeneity in tumor cell staining is commonly seen with variability between areas of the tissue section, between fields and within a gland. Tumor cell staining is most often linear. The relative percentage of neoplastic cells staining at moderate and strong membrane intensity is estimated to give the CLDN18 IHC status of either positive or negative for the case. For each case, the matched negative control slide is used to assess non-specific background staining and the degree of background staining.

Evaluating Staining Patterns and Intensities

The VENTANA CLDN18 (43-14A) Rx Dx Assay exhibits membranous staining pattern with a varying range of intensities (weak, moderate, and strong) in non-neoplastic gastric tissue, intestinal metaplasia and in gastric adenocarcinoma including the GEJ.

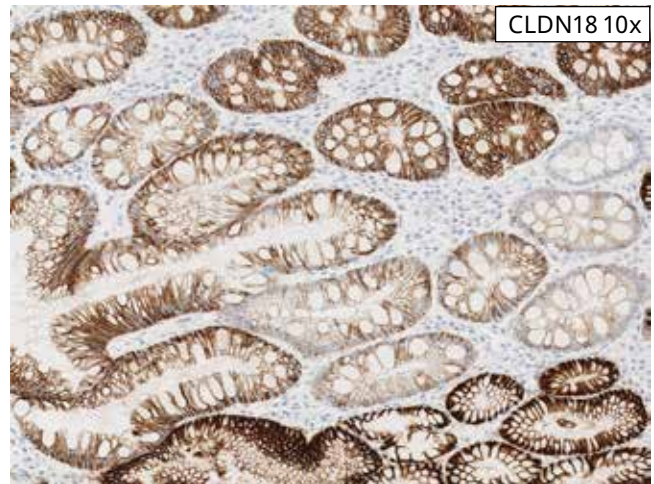
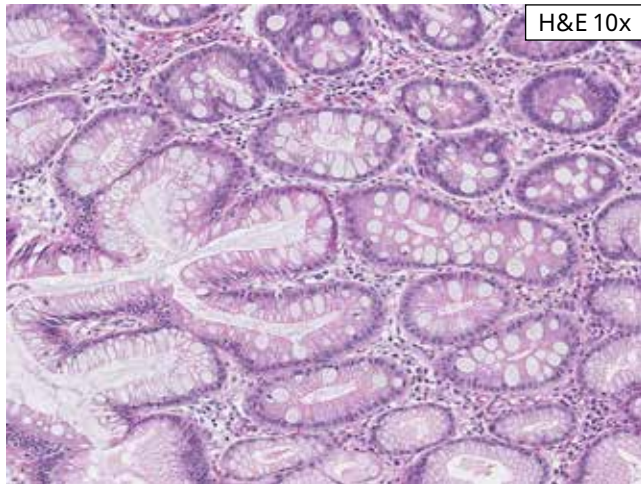
- Weak intensity is staining with a light brown hue, and the membrane staining may appear to be partial or circumferential
- Moderate intensity is staining with a chocolate brown hue, and the membrane staining may appear to be partial or circumferential
- Strong intensity is staining with a dark brown to black hue, saturated DAB, and the membrane staining is thickened and may be partial or circumferential

Non-neoplastic Gastric Epithelium: Strong membrane staining is seen in non-neoplastic gastric epithelium that may be present in the tissue section. This is useful as an internal positive control, but IS NOT REQUIRED for assay interpretation. Cytoplasmic staining can also be seen but is not included in the scoring algorithm.

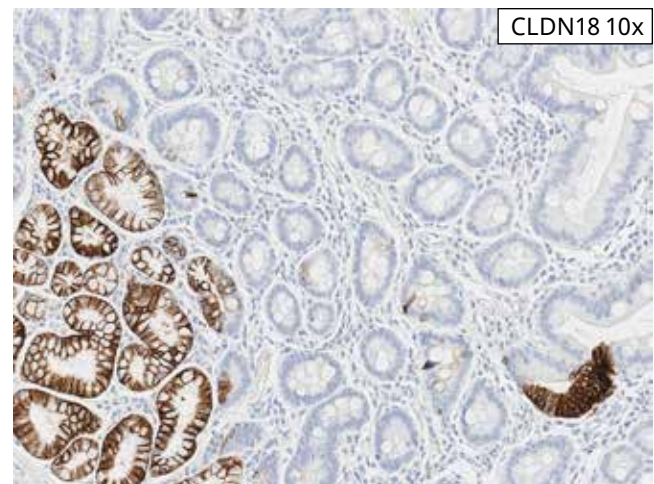
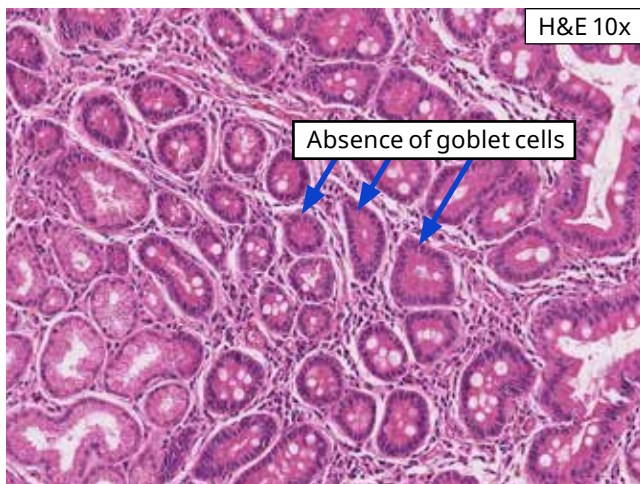


Non-neoplastic Gastric Epithelium Case: Strong membrane staining is seen in non-neoplastic gastric epithelium. Focal cytoplasmic staining is present, but is not included in scoring.

Intestinal Metaplasia: The full spectrum of CLDN18 staining intensity may be seen in intestinal metaplasia (if present) in the gastric tissue section. Acceptability criteria for CLDN18 staining of intestinal metaplasia apply to the system level control ONLY (**Table 2**). Intestinal metaplasia is NOT REQUIRED within the gastric tissue section for assay interpretation.



Intestinal Metaplasia: Absent to strong membrane staining is seen in intestinal metaplasia in this case. The presence of intestinal metaplasia is NOT REQUIRED in a gastric tissue section for assay interpretation.



Intestinal metaplasia: The H&E image on the left shows non-neoplastic gastric epithelium (lower left corner) and intestinal metaplasia with goblet cells. The metaplastic intestinal epithelium in the center of the image does not have goblet cells. In the image of the CLDN18-stained tissue on the right, the non-neoplastic gastric epithelium shows strong membrane staining, while there is minimal to no staining of the metaplastic intestinal epithelium. Do not immediately interpret epithelium without goblet cells as non-neoplastic gastric epithelium which is not staining appropriately. Be aware that goblet cells may not always be present in the metaplastic intestinal epithelium.

Tumor Cell Scoring

Tumor cell CLDN18 membrane staining is scored as the percentage of viable tumor cells showing moderate to strong membrane staining of the total number of viable tumor cells. Membrane staining should be visible as a linear staining, even if associated with a granular quality.

Only viable tumor is considered for total number of tumor cells. Tumor cell staining within areas of necrosis or within intraluminal necrotic debris is excluded. Tumor cell scoring criteria is provided in [Table 1](#).

For each patient specimen, the VENTANA CLDN18 (43-14A) RxDx Assay requires one serial tissue section for hematoxylin and eosin (H&E) staining, a second serial tissue section for negative control antibody staining (negative reagent control, NRC (Cat. No. 760-2014 / 05266670001), and a third serial tissue section for VENTANA CLDN18 (43-14A) staining. The CLDN18-stained specimen slides should be assessed by a trained pathologist. A CLDN18 IHC status can be generated when all the controls (SLC and NRC) show acceptable results.

If the H&E evaluation indicates that the patient specimen is inadequate (for example, if fewer than 50

viable tumor cells are present), then a new specimen should be obtained. If the CLDN18-stained SLC slide is not acceptable, the staining of patient samples on that staining run should be repeated. If the NRC slide is unacceptable, the test should be repeated with a new set of test tissue sections for that case.

Repeat staining of a specimen should be carried out on unstained slides if (1) the tissue does not exhibit acceptable H&E staining; (2) the negative control case slide exhibits unacceptable staining; or (3) the VENTANA CLDN18 (43-14A) RxDx Assay-stained case slide (the “CLDN18 IHC slide”) is not evaluable. A non-evaluable slide stained with VENTANA CLDN18 (43-14A) RxDx Assay would mean that determination of IHC reactivity is not possible due to artifacts (edge effect, DAB trapping, tissue folding and/or tearing), excessive background, necrosis, lack of tissue, lack of tumor, or any other reason. If the CLDN18 IHC slide is not interpretable, then the slide cannot be used for clinical evaluation. See [Specimen Flow](#).

Table 1: Tumor Cell Scoring Criteria

Tumor Cell Scoring	What to Include
Cells Included	Greater than 50 Viable Tumor Cells Only
Staining Intensity	Moderate to Strong
Pattern of Staining	Apical, Circumferential (partial and complete), Basolateral/Lateral, Microluminal
Denominator for Scoring	Total Number of Viable Tumor Cells

Morphology and Background Acceptability Criteria

Tissue morphology and background acceptability are assessed for each patient case using the criteria described in **Tables 2** and **3**.

Table 2: Morphology Acceptability Criteria

Interpretation	Microscope Observation
Acceptable	Cellular elements of interest are visualized allowing clinical interpretation of the stain
Not Acceptable	Cellular elements of interest are not visualized compromising the clinical interpretation of the stain

Table 3: Background Acceptability Criteria

Interpretation	Microscope Observation
Acceptable	Non-specific staining is not obtrusive to interpretation of specific staining
Not Acceptable	Non-specific staining is obtrusive to interpretation of specific staining

Scoring Algorithm

VENTANA CLDN18 (43-14A) RxDx Assay staining can be observed in tumor cells of gastric and GEJ adenocarcinoma tissues, which exhibit a membranous staining pattern with a varying range of stain intensity.

- Weak intensity is staining with a light brown hue, and the membrane staining may appear to be partial or circumferential
- Moderate intensity is staining with a chocolate brown hue, and the membrane staining may appear to be partial or circumferential
- Strong intensity is staining with a dark brown to black hue, saturated DAB, and the membrane staining is thickened and may be partial or circumferential

CLDN18 IHC status is assigned by a trained pathologist based on percent moderate to strong CLDN18 viable

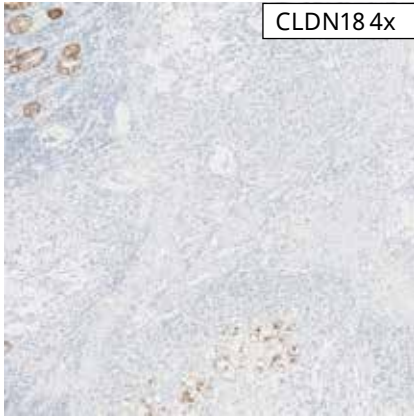
tumor cell membrane staining. VENTANA CLDN18 (43-14A) RxDx Assay Scoring Algorithm is described in **Table 4**.

Gastric and GEJ adenocarcinoma tissues stained with the VENTANA CLDN18 (43-14A) RxDx Assay are scored for percent tumor cell staining, which is defined as the proportion of viable tumor cells exhibiting membrane staining of moderate or stronger intensity out of the total number of viable tumor cells. Membrane staining pattern may be apical, circumferential (partial or complete), basolateral/lateral or microluminal. Gastric and GEJ adenocarcinoma tissue cases are considered positive for CLDN18 IHC status if $\geq 75\%$ of viable tumor cells demonstrate CLDN18 expression at intensities at or above moderate membrane staining.

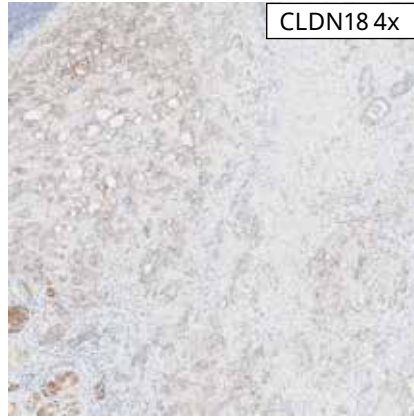
Table 4: Scoring Algorithm for Gastric Adenocarcinoma Including the Gastroesophageal Junction (75% Cut-Off)

IHC Interpretation	Staining Description
Positive	$\geq 75\%$ viable tumor cells demonstrating moderate to strong membrane CLDN18 staining
Negative	$< 75\%$ viable tumor cells demonstrating moderate to strong membrane CLDN18 staining

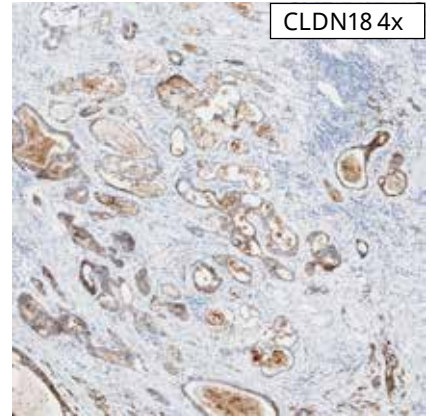
NEGATIVE: < 75% CLDN18 STAINING



5% tumor cell membrane staining

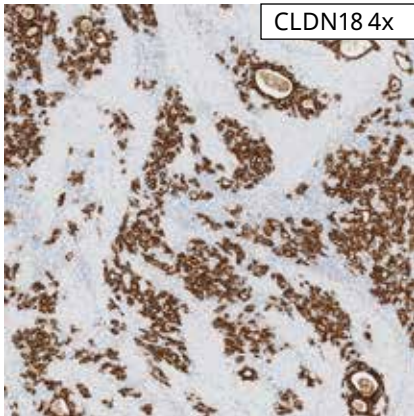


20% tumor cell membrane staining

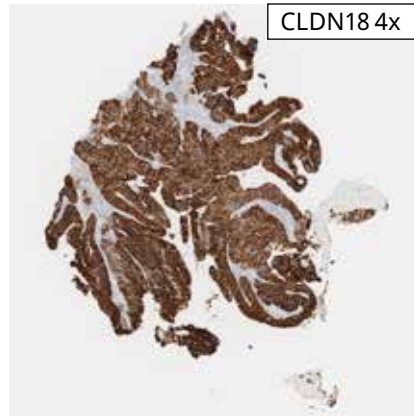


70% tumor cell membrane staining

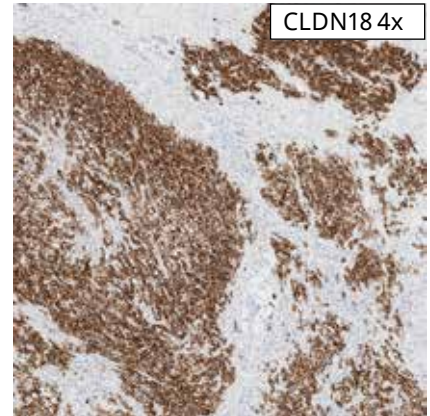
POSITIVE: ≥ 75% CLDN18 STAINING



100% tumor cell membrane staining

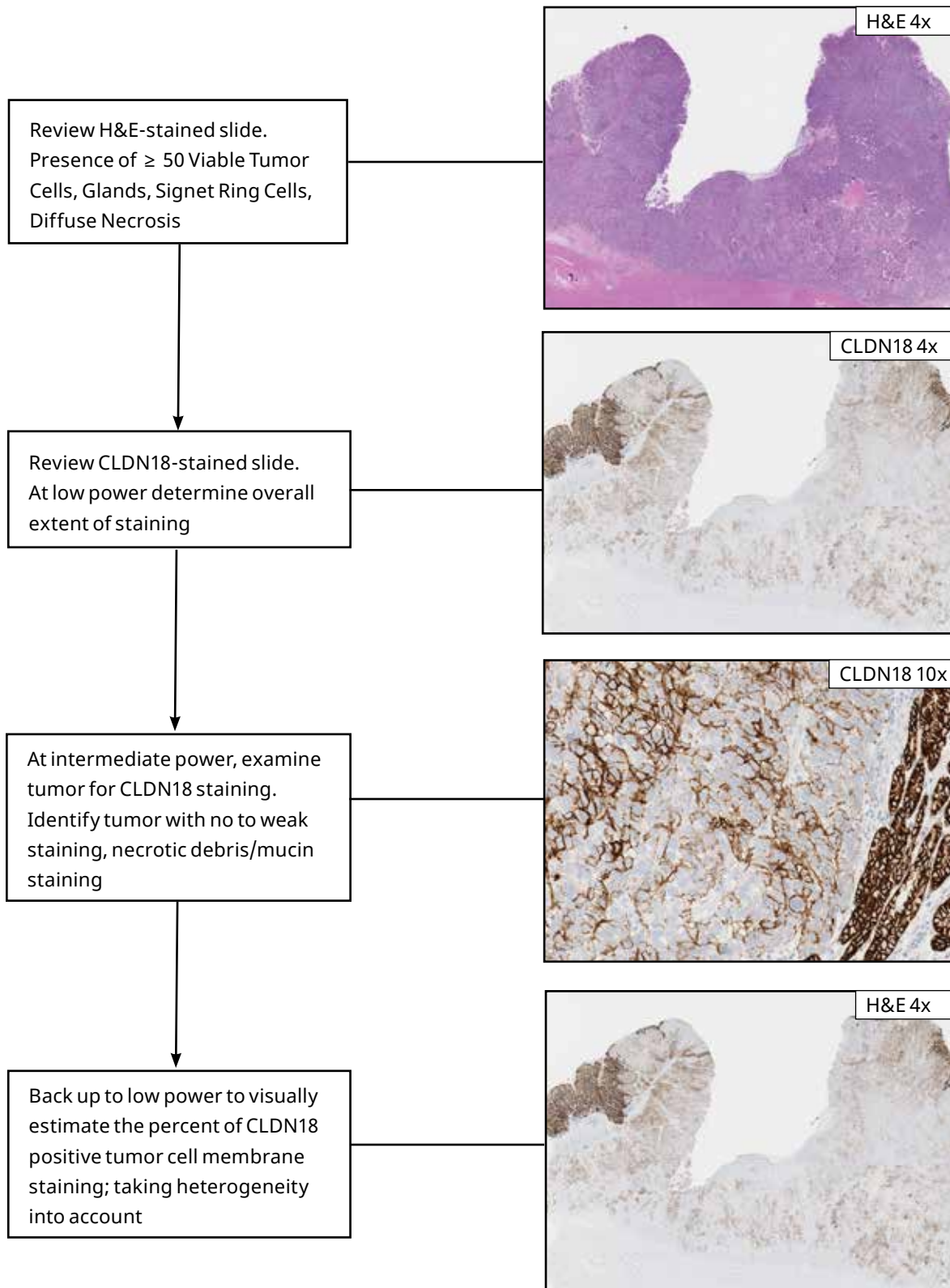


95% tumor cell membrane staining



100% tumor cell membrane staining

Scoring Method



System Level Control

A System Level Control (SLC) helps identify instrument or reagent failures during the staining procedure. SLC tissue is obtained from a fresh biopsy or surgical specimen, prepared and fixed as soon as possible, and processed in a manner identical to the test sections. SLC should be utilized only for monitoring performance of reagents and instruments, and not as an aid in determining specific diagnosis of test samples. If the SLC fail to demonstrate appropriate positive or negative staining, results of the test specimen should be considered invalid.

For VENTANA CLDN18 (43-14A) RxDx Assay, a SLC that is stained in the same manner as the patient specimens should be run for each set of test conditions to monitor the proper functioning of the reagents and instrument within the staining run. SLC tissue should be fixed and processed in the same manner as the patient specimens. A tissue section fixed or processed differently from the

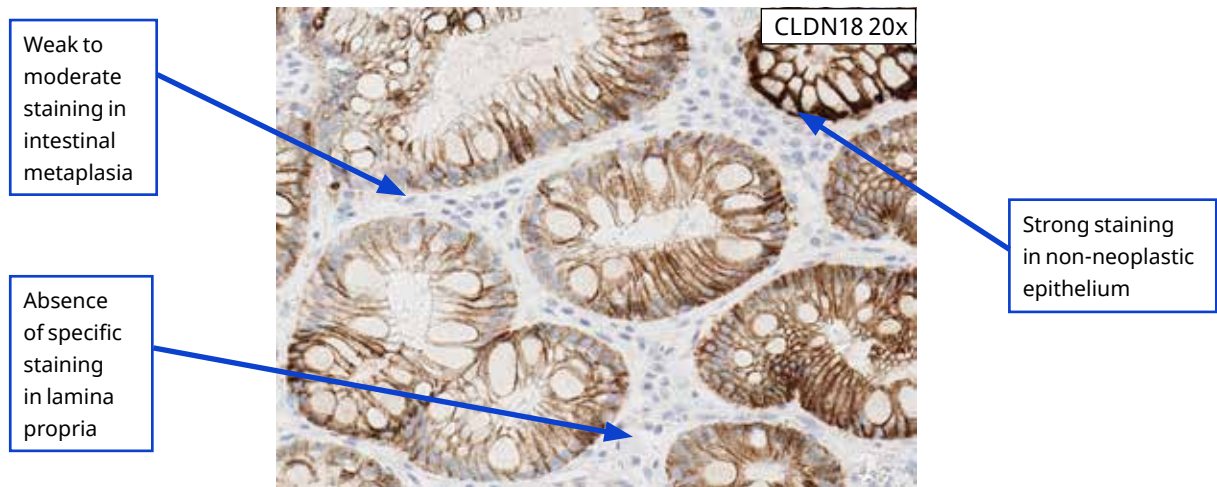
test specimen can be used as a control for reagents and staining but does not control for pre-analytic variation (fixation or tissue preparation). Tissue specimens with autolysis, degeneration, or improper fixation should not be used as SLC.

Pre-qualified human gastric tissue with intestinal metaplasia, containing both CLDN18-positive and CLDN18-negative staining elements, can be used as SLC for VENTANA CLDN18 (43-14A) RxDx Assay. A proper SLC should exhibit the presence of strong membranous CLDN18 staining of non-neoplastic gastric epithelial cells, the presence of weak to moderate membranous CLDN18 staining of metaplastic intestinal epithelial cells, and the absence of CLDN18 staining in lamina propria, lymphocytes, smooth muscle, blood vessels, and peripheral nerve ([Table 5](#)).

Table 5: VENTANA CLDN18 (43-14A) RxDx Assay Scoring Criteria for Evaluation of Gastric Tissue with Intestinal Metaplasia SLC

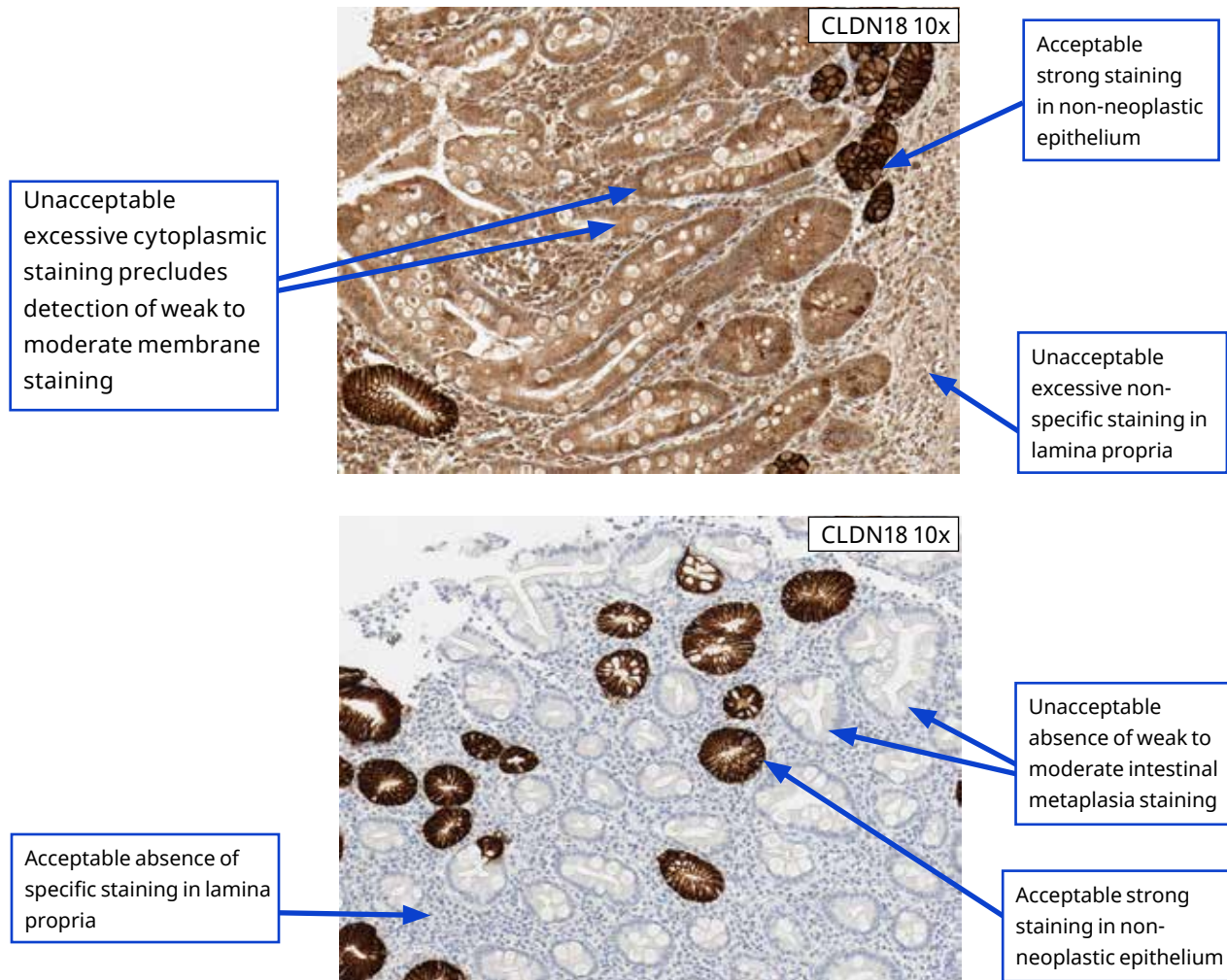
	Acceptable	Unacceptable
Positive	Presence of strong membranous CLDN18 staining in normal gastric epithelial cells AND Presence of weak to moderate membranous CLDN18 staining of epithelial cells in the areas of metaplasia	Absence of any strong membranous CLDN18 staining in normal gastric epithelial cells OR Absence of weak to moderate membranous CLDN18 staining of epithelial cells in the areas of metaplasia
Negative	Absence of CLDN18 staining in lamina propria, lymphocytes, smooth muscle, blood vessels, and peripheral nerve	Excessive non-specific background staining of lamina propria, lymphocytes, smooth muscle, blood vessels, and peripheral nerve obscuring the evaluation of CLDN18 stained cells

Acceptable Positive and Negative Staining Elements in SLC Tissue



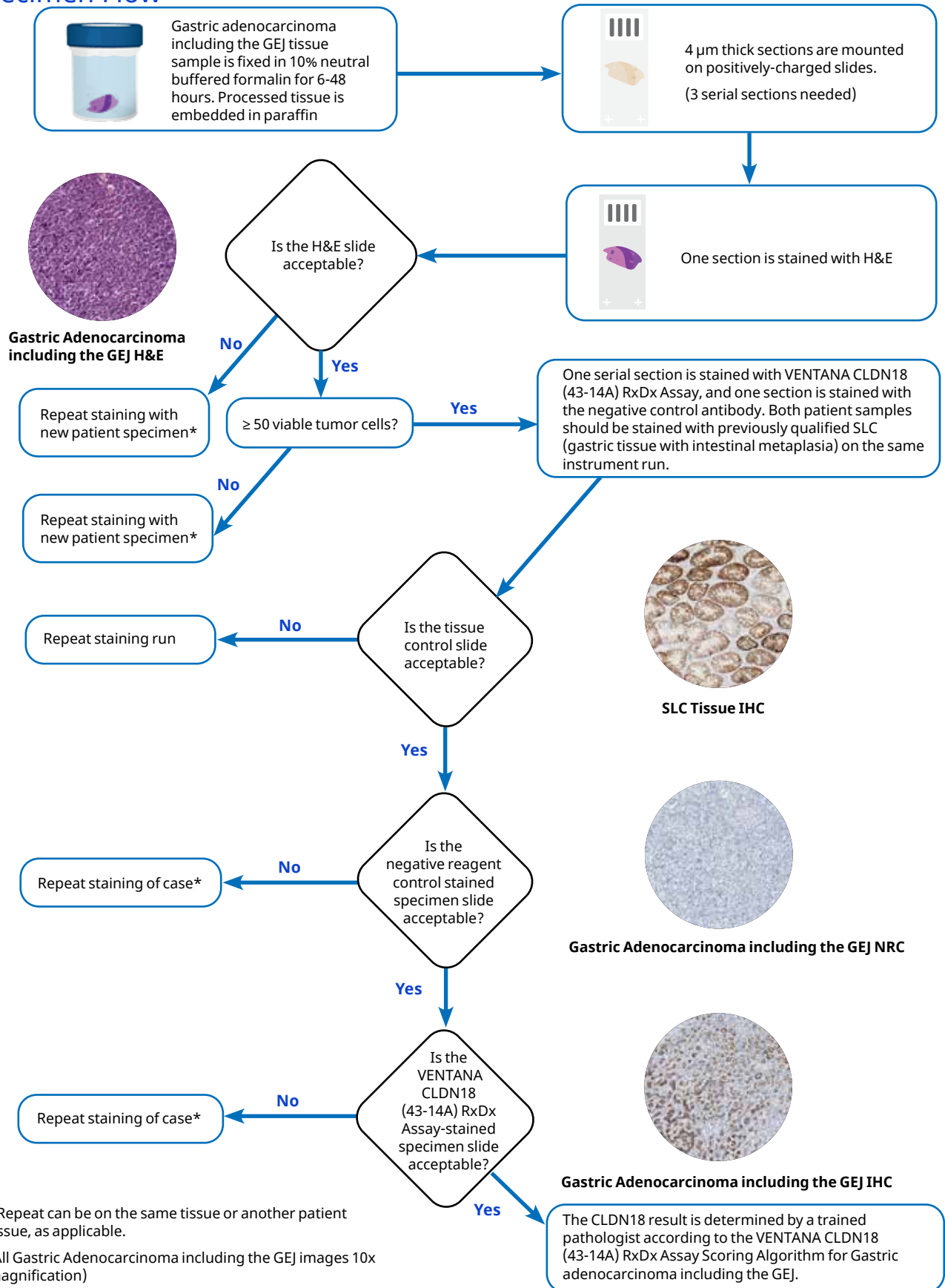
Acceptable Positive and Negative Staining Elements in SLC Tissue should exhibit strong membranous staining in non-neoplastic gastric epithelial cells, weak to moderate membranous staining of metaplastic intestinal epithelial cells, and the absence of staining in negative staining elements (lamina propria, lymphocytes, smooth muscle, blood vessels, and peripheral nerve).

Unacceptable Positive and Negative Staining Elements in SLC Tissue



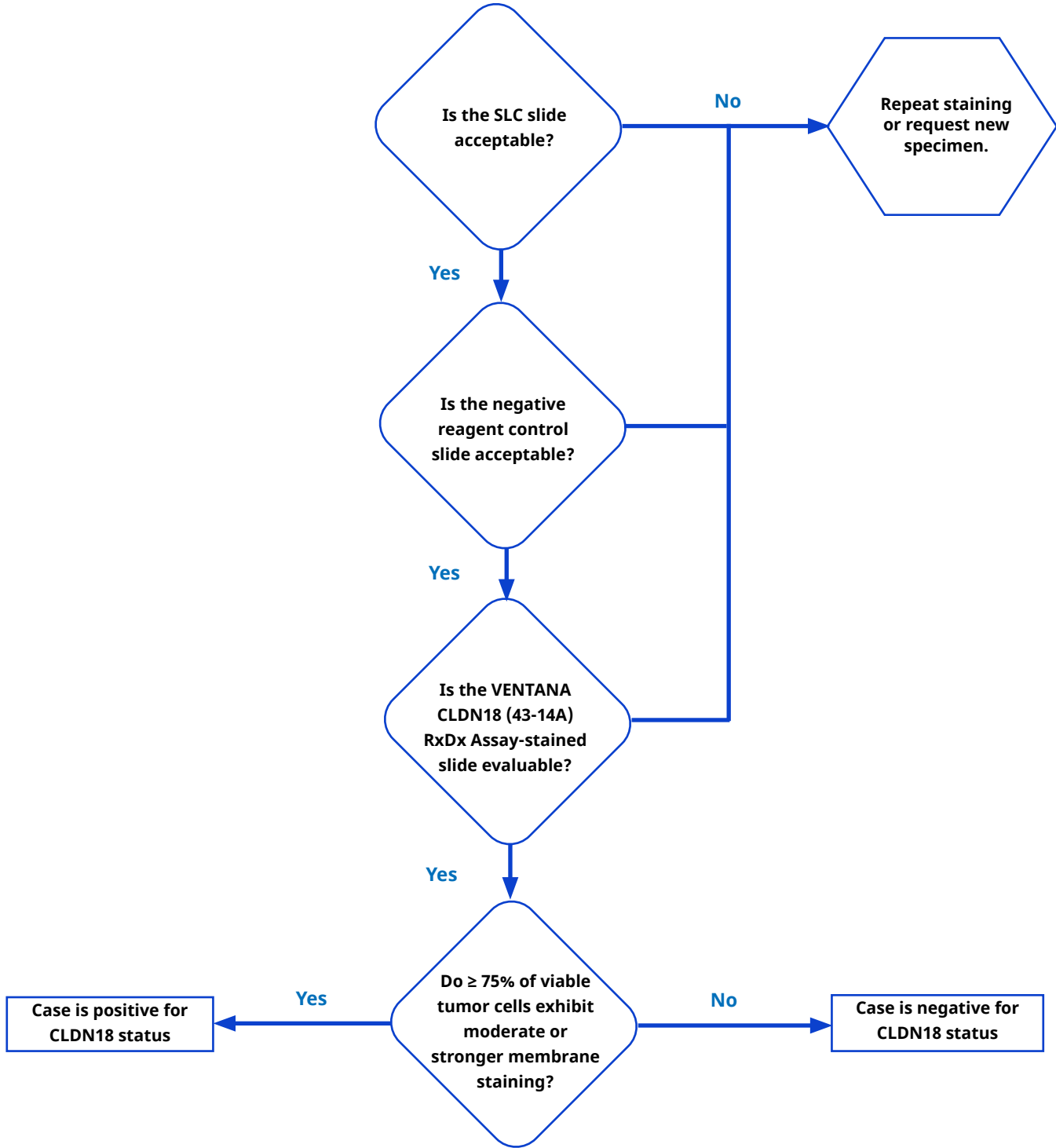
Unacceptable Positive and Negative Staining Elements in SLC Tissue: While the image on the top exhibits strong membranous staining in non-neoplastic gastric epithelial cells, there is no detectable weak to moderate membranous staining of metaplastic intestinal epithelial cells, and staining is seen in elements (lamina propria, lymphocytes, and blood vessels) which should be negative. In addition, there is diffuse cytoplasmic staining. The image on the bottom shows appropriate strong membranous staining of the non-neoplastic gastric epithelium and absence of staining in negative elements, but there is no weak to moderate staining of the metaplastic intestinal epithelium. Both of these scenarios demonstrate unacceptable staining of gastric tissue with intestinal metaplasia in SLC slides.

Specimen Flow



Decision Tree

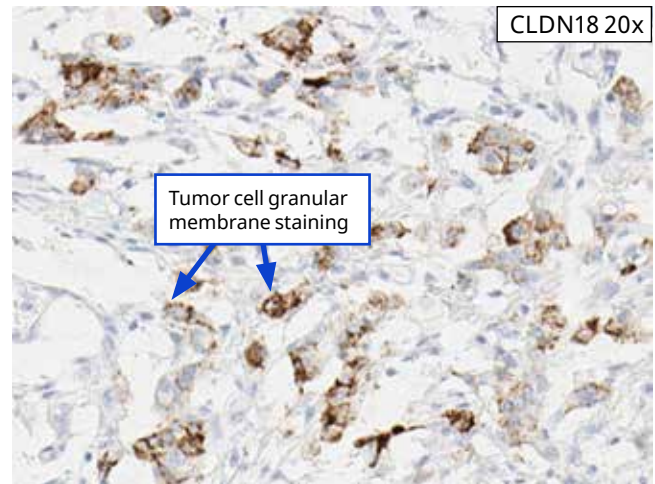
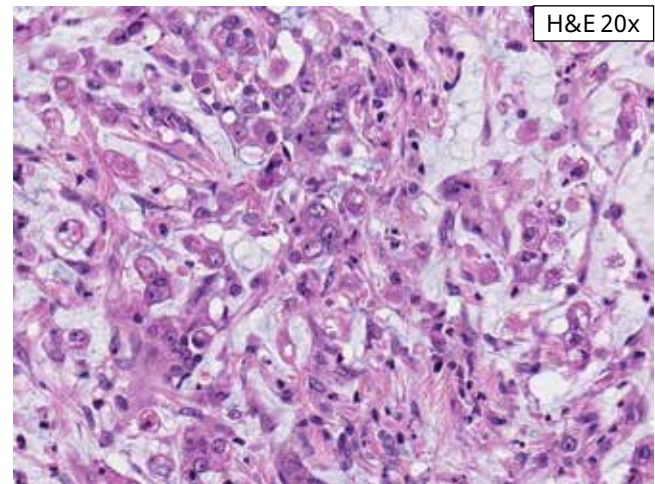
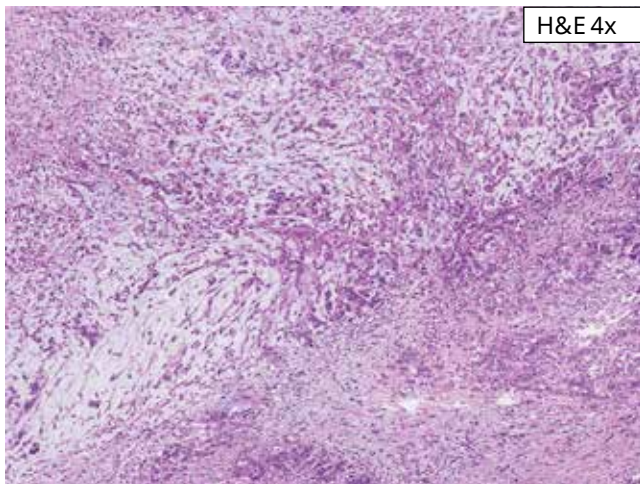
Slides stained with the VENTANA CLDN18 (43-14A) RxDx Assay should be evaluated using [Table 4](#) and the approach summarized in the decision tree below.



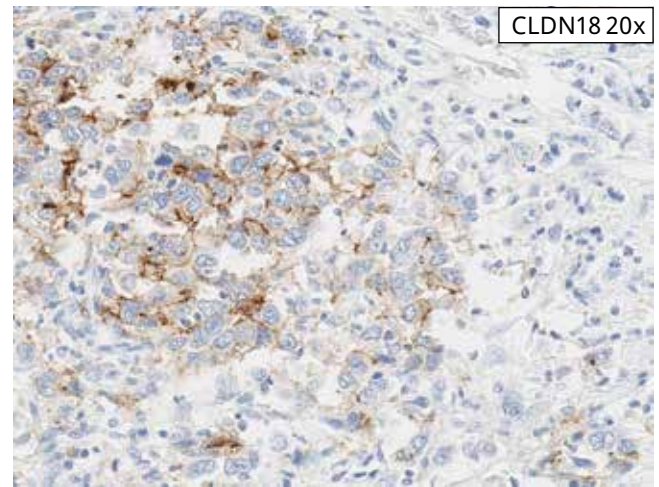
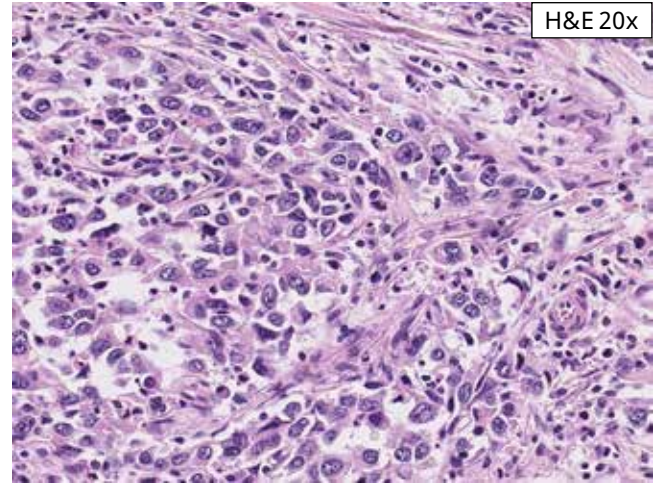
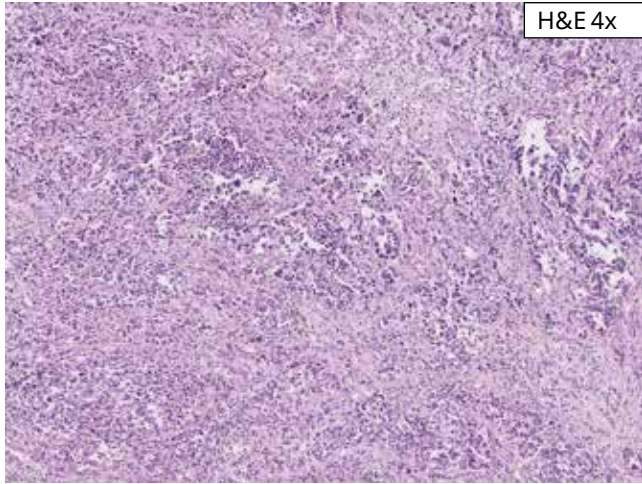
Reference Images

Negative Cases

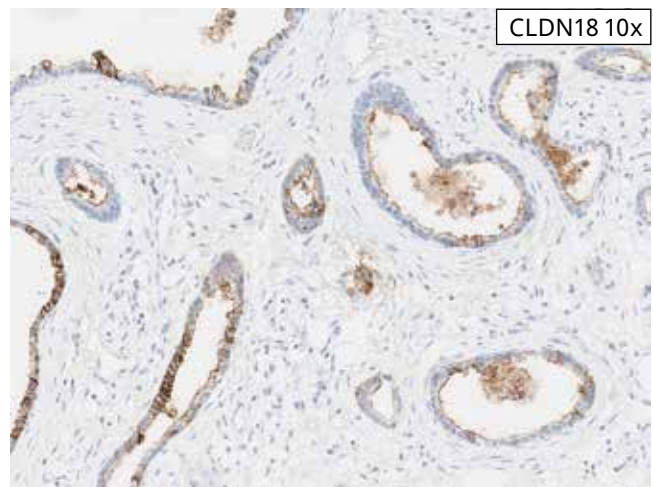
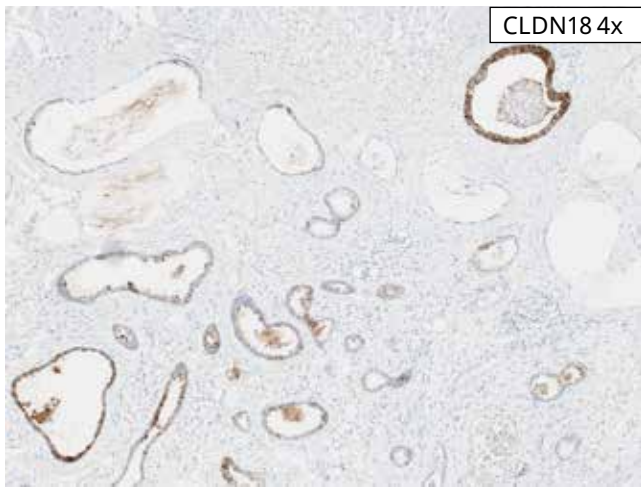
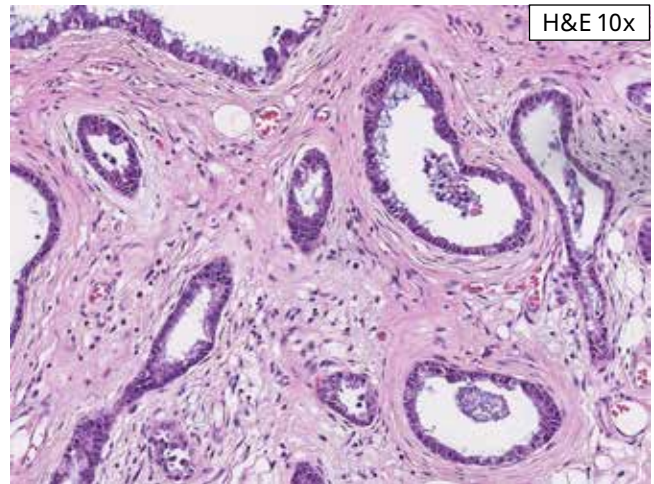
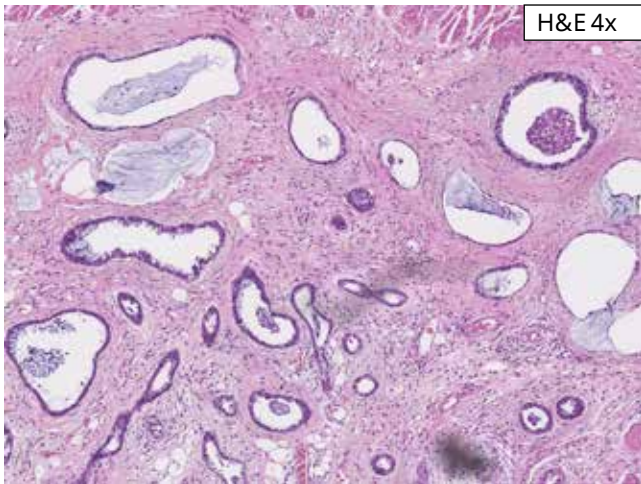
A case with a negative CLDN18 IHC status is characterized by < 75% viable tumor cells demonstrating moderate to strong CLDN18 membrane staining with acceptable background.



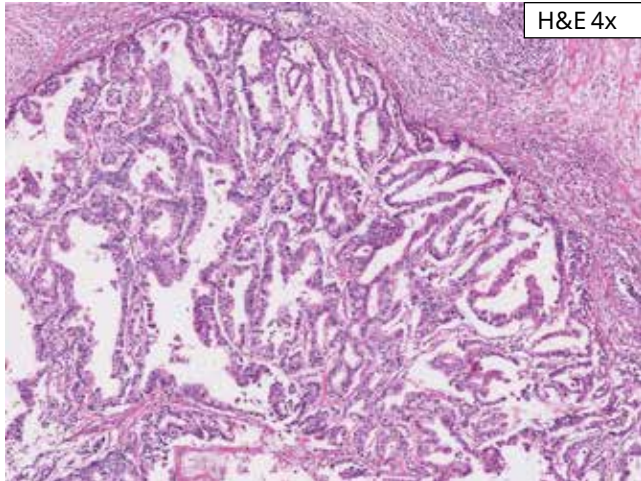
Negative Case 1: Granular membrane staining is seen in this case of diffuse gastric cancer. Granular membrane staining counts as positive staining if moderate to strong and is aligned along the tumor cell membrane. The case exhibits 25% CLDN18 staining and is negative for CLDN18 IHC status.



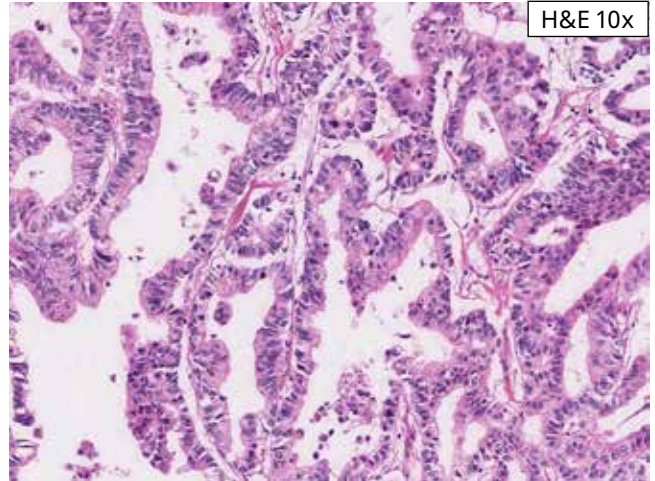
Negative Case 2: This case exhibits moderate to strong membrane staining in 30% of tumor cells. This case is negative for CLDN18 IHC status.



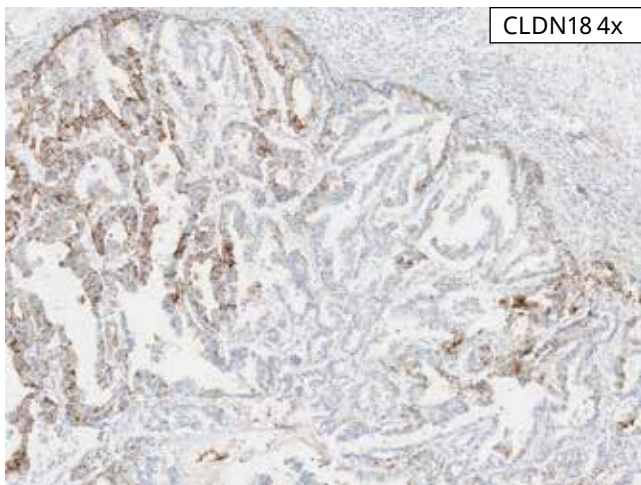
Negative Case 3: This case exhibits moderate to strong staining in 40% of tumor cells. This case is negative for CLDN18 IHC status.



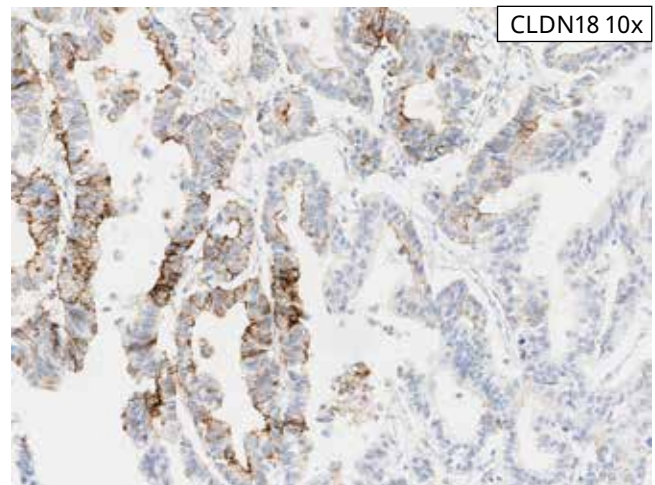
H&E 4x



H&E 10x

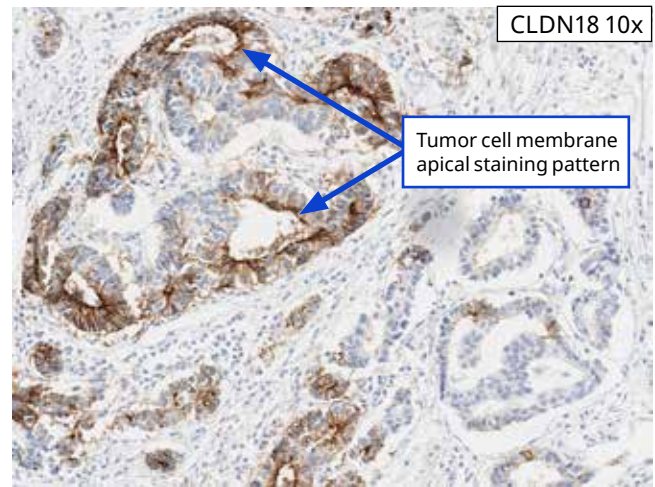
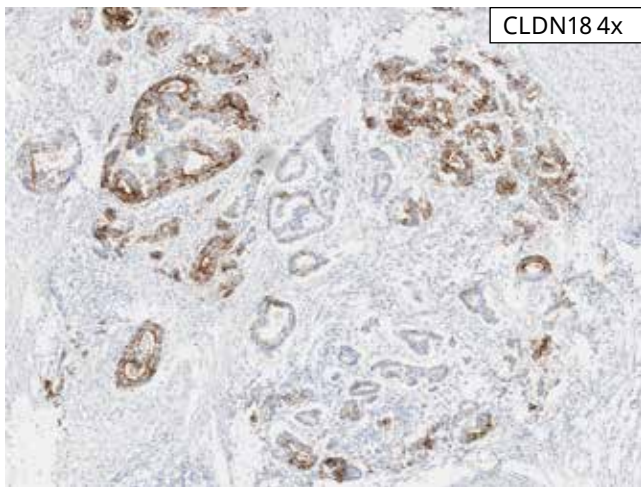
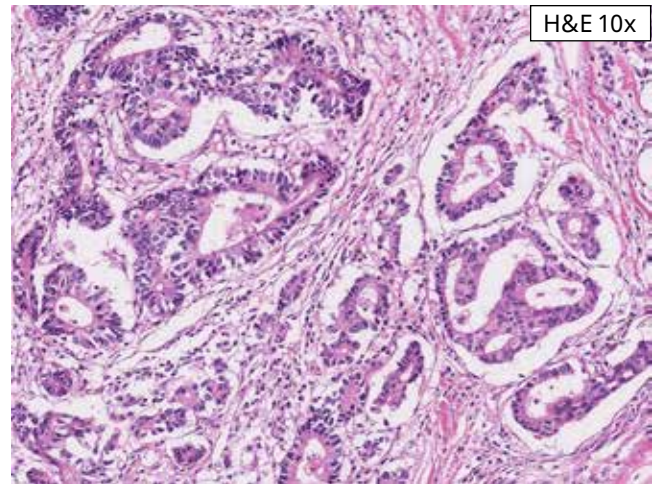
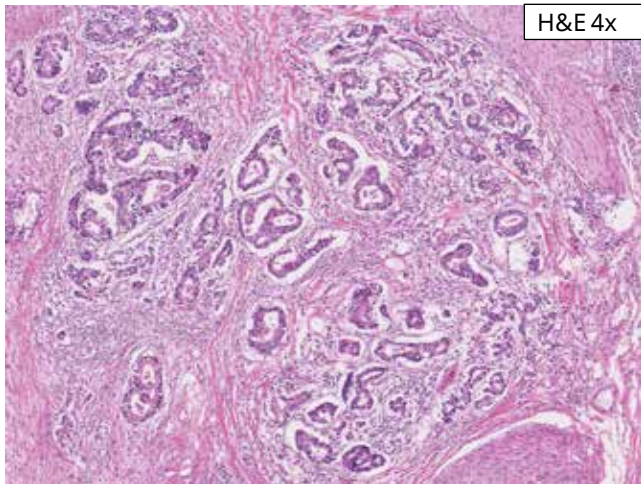


CLDN18 4x



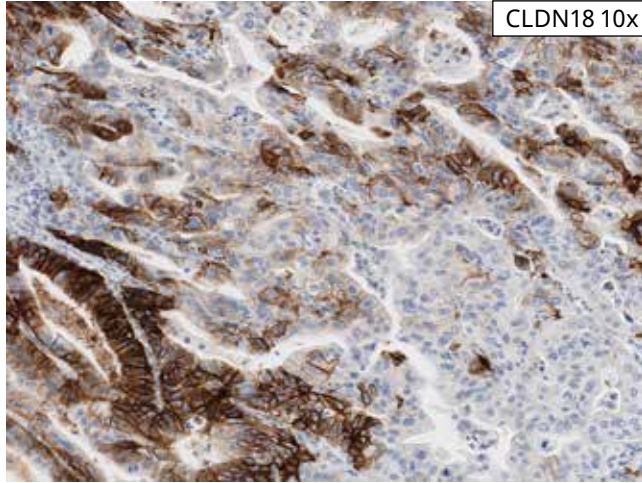
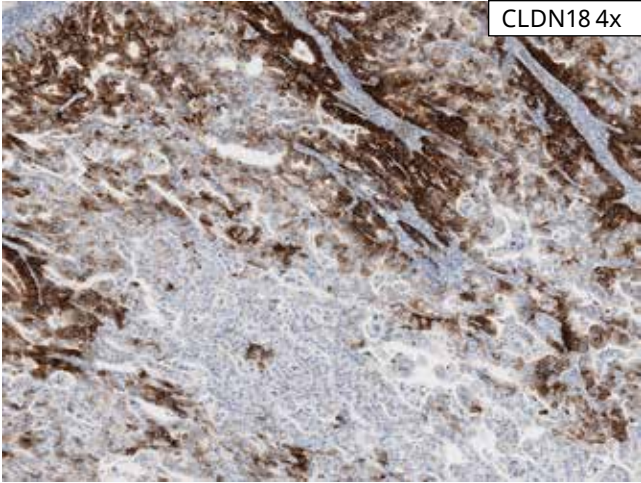
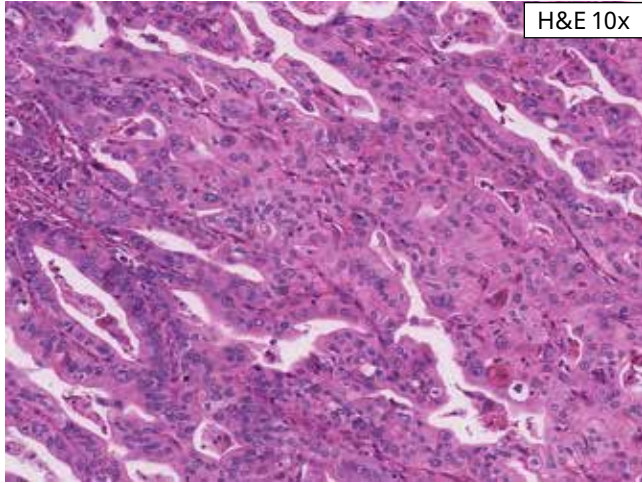
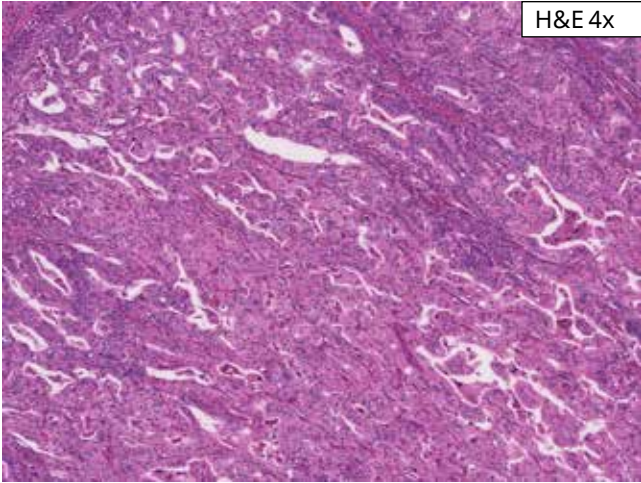
CLDN18 10x

Negative Case 4: This case exhibits moderate to strong membrane staining in 50% of tumor cells. The staining pattern in this case is predominantly basolateral/lateral; apical staining is also present. This case is negative for CLDN18 IHC status.

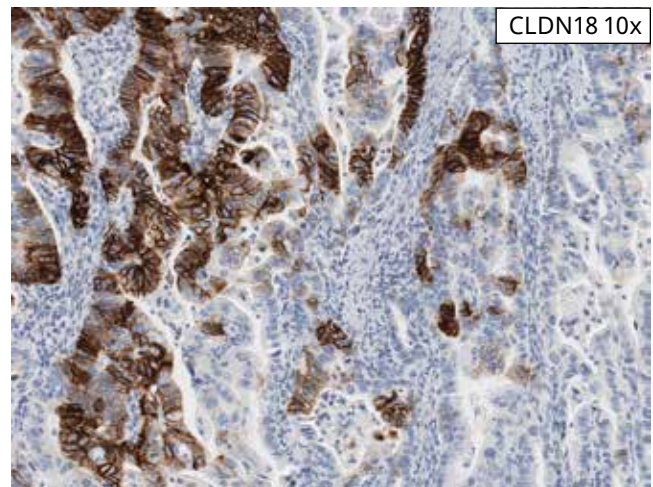
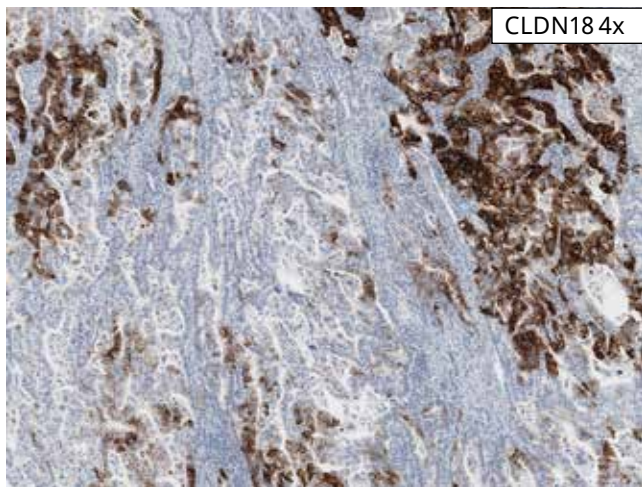
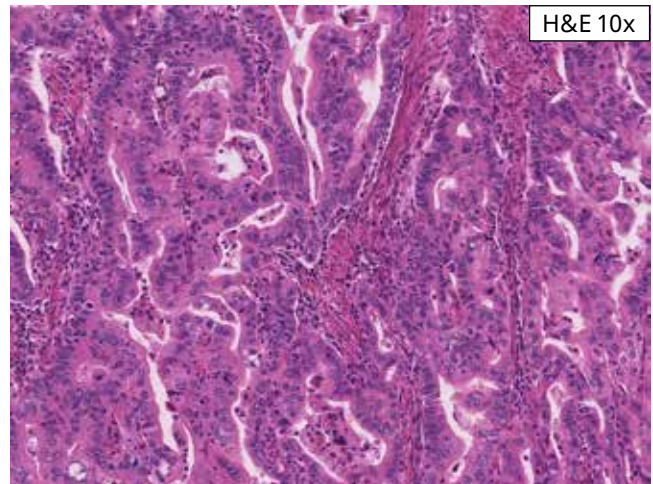
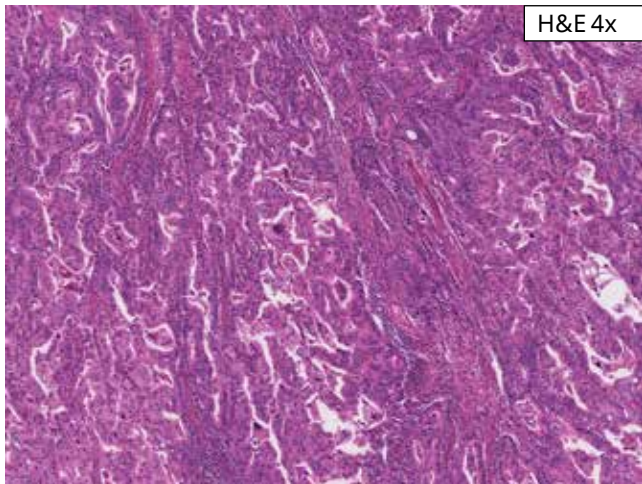


Negative Case 5: This case exhibits moderate to strong membrane staining in 60% of tumor cells. The membrane staining pattern is predominantly apical. This case is negative for CLDN18 IHC status.

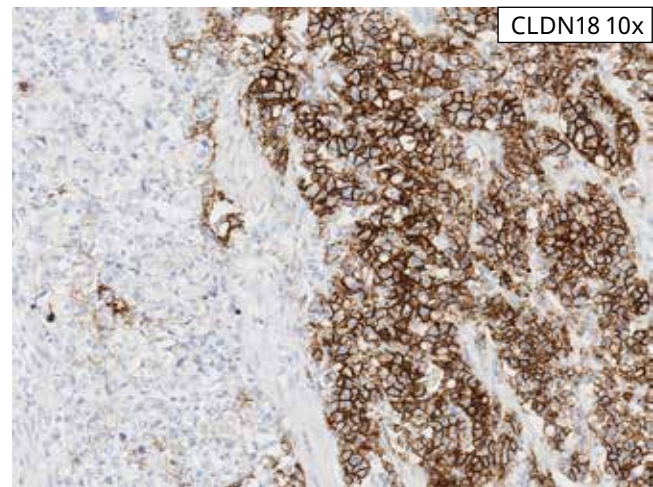
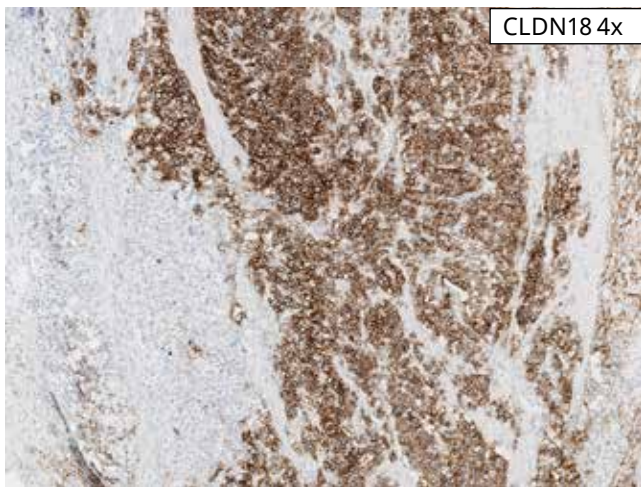
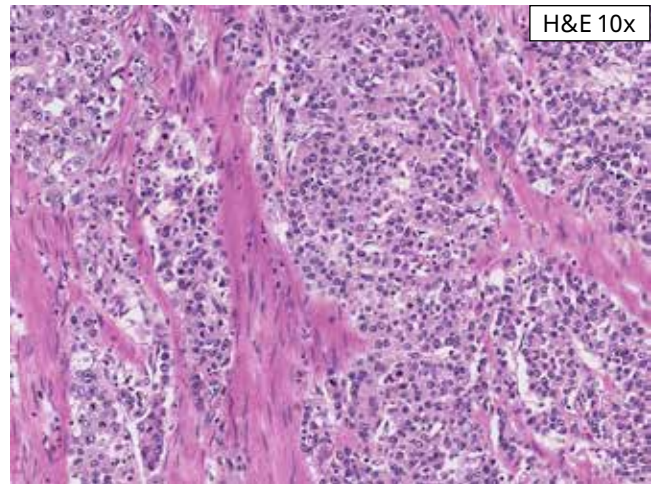
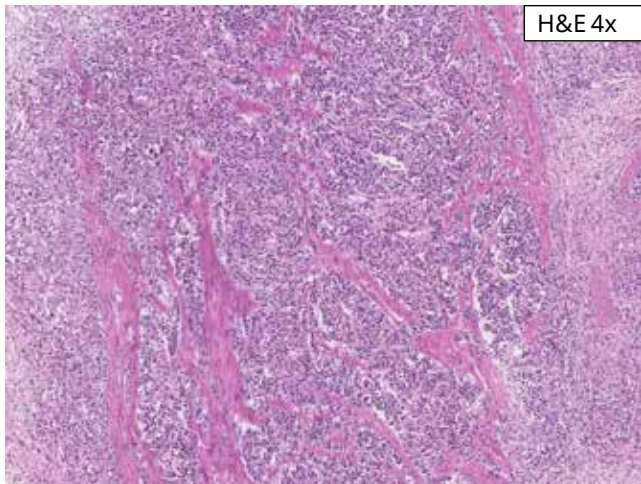
Borderline Cases



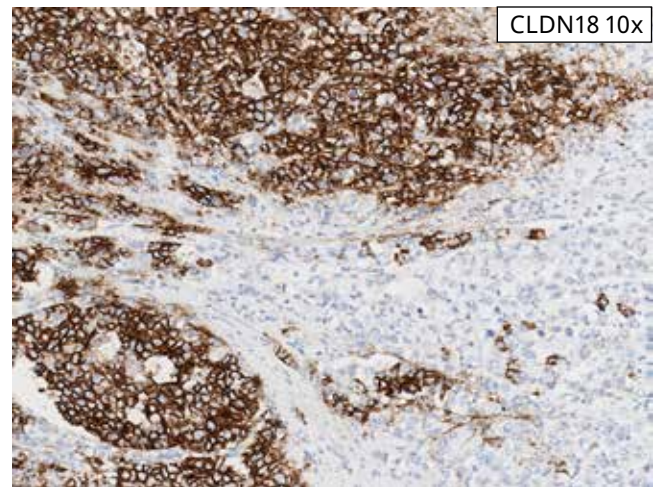
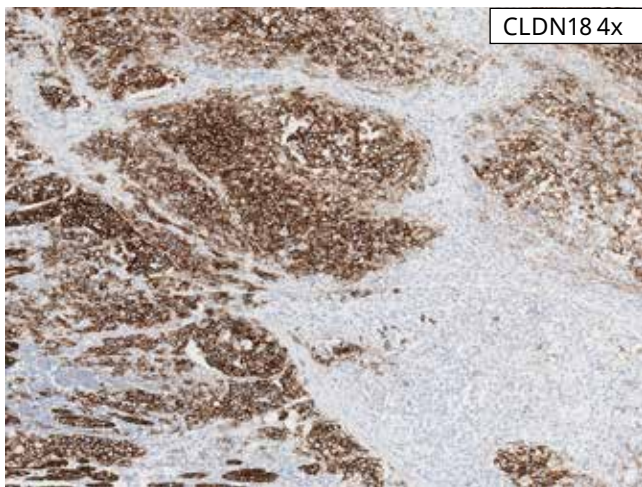
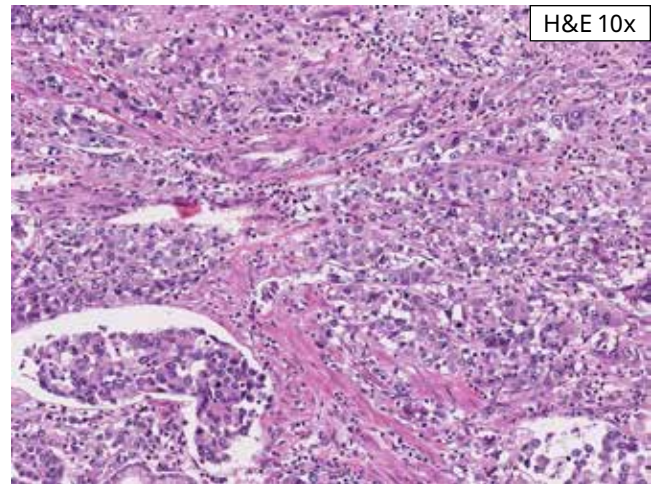
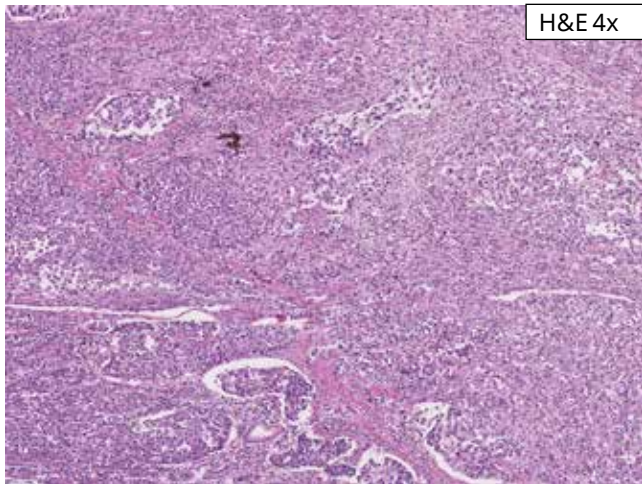
Borderline Case 1: This case exhibits moderate to strong membrane staining in 65% of tumor cells. This case is borderline negative for CLDN18 IHC status.



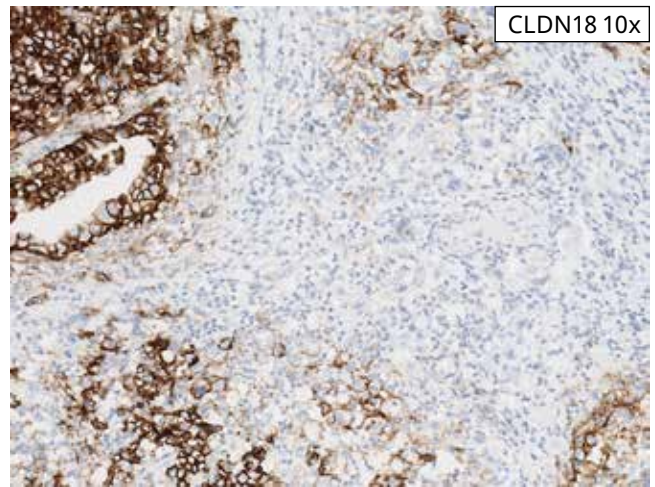
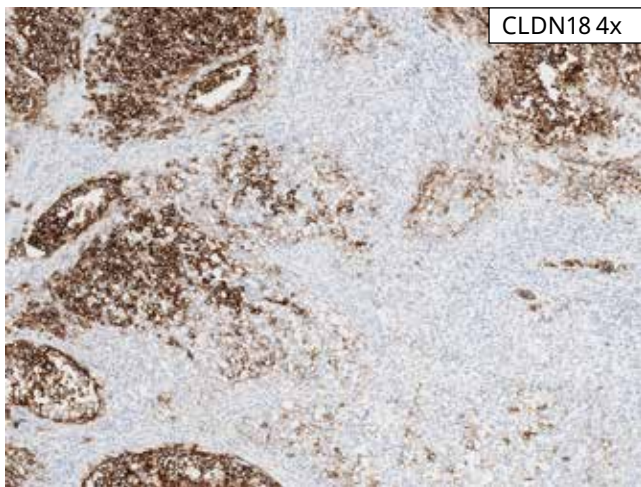
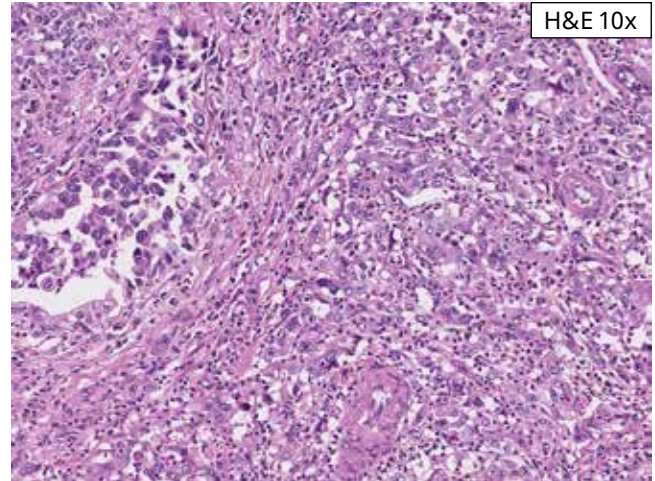
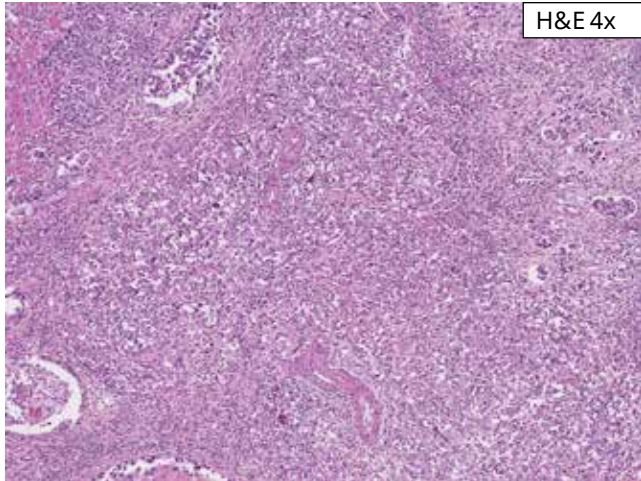
Borderline Case 2: This case exhibits 65% moderate to strong staining in a predominantly basolateral/lateral pattern. This case is borderline negative for CLDN18 IHC status.



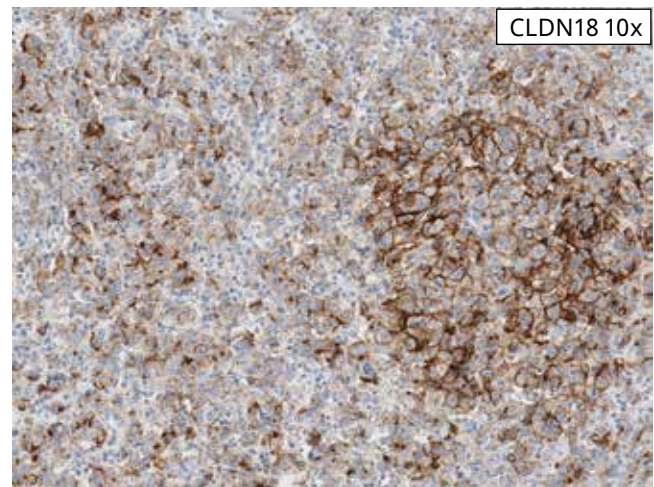
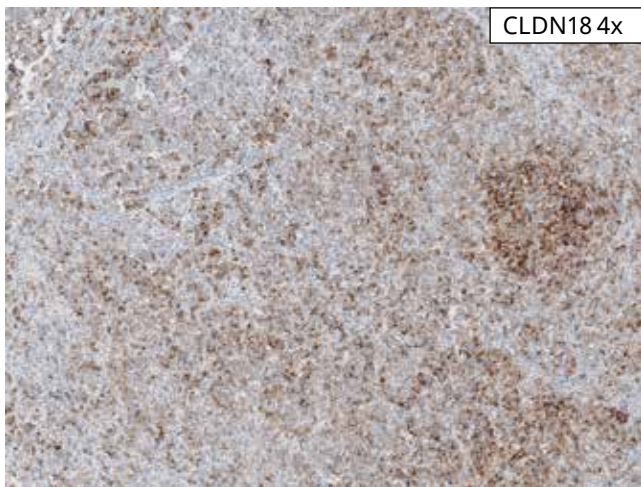
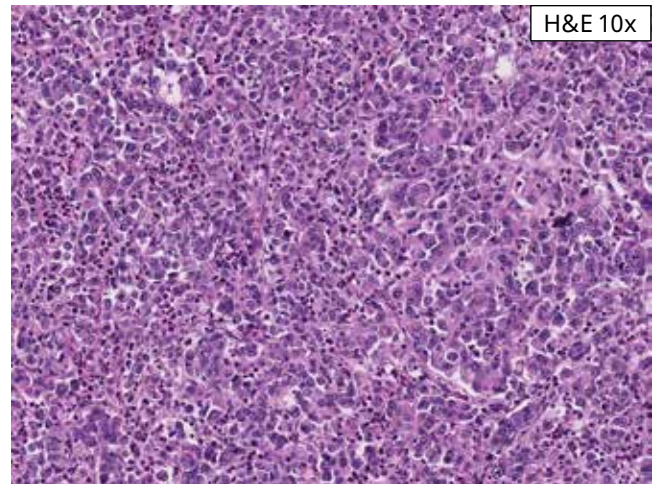
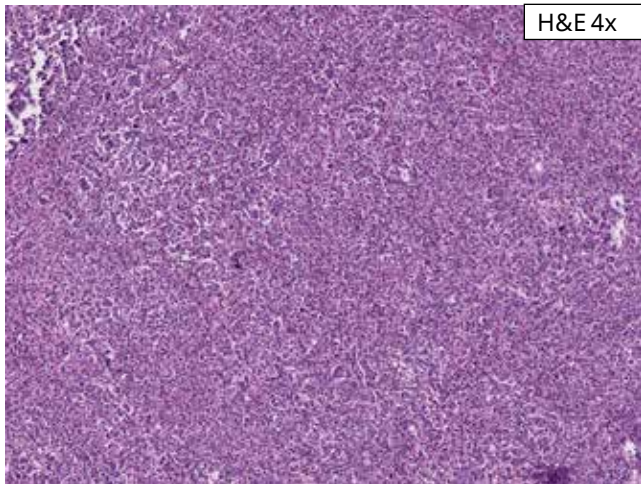
Borderline Case 3: This case exhibits 65% moderate to strong staining in a predominantly circumferential pattern. This case is borderline negative for CLDN18 IHC status.



Borderline Case 4: This case exhibits moderate to strong membrane staining in 75% of the tumor cells. These tumor cells also show strong cytoplasmic staining, which is not included in scoring. This case is borderline positive for CLDN18 IHC status.



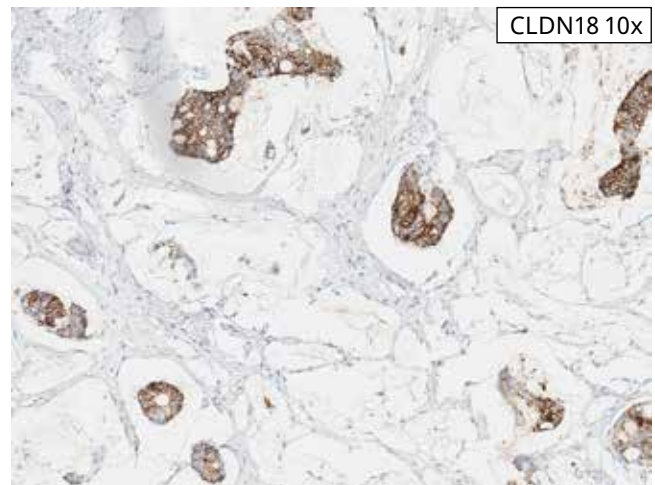
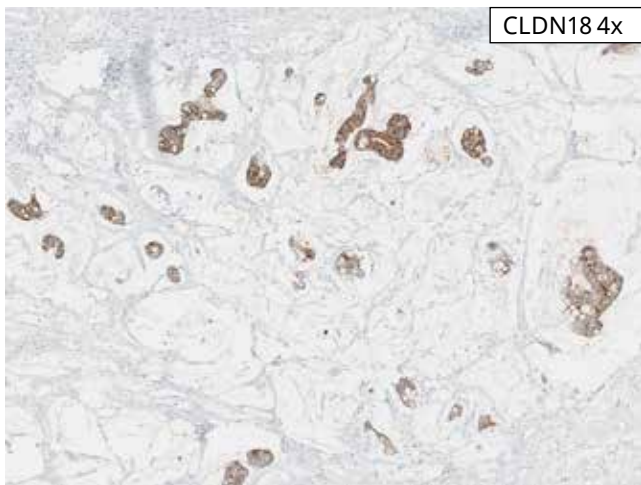
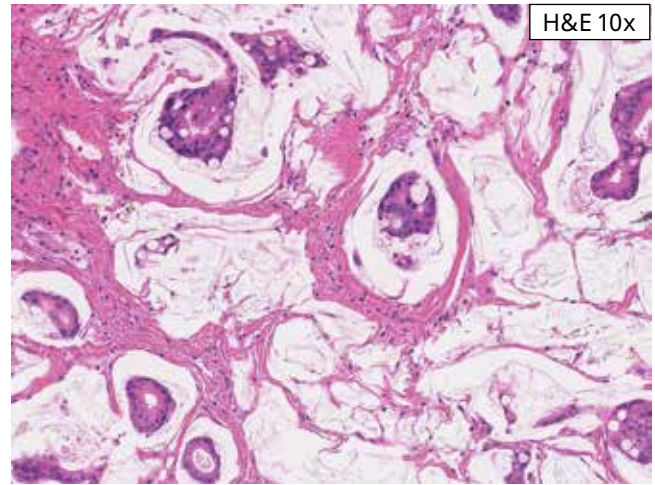
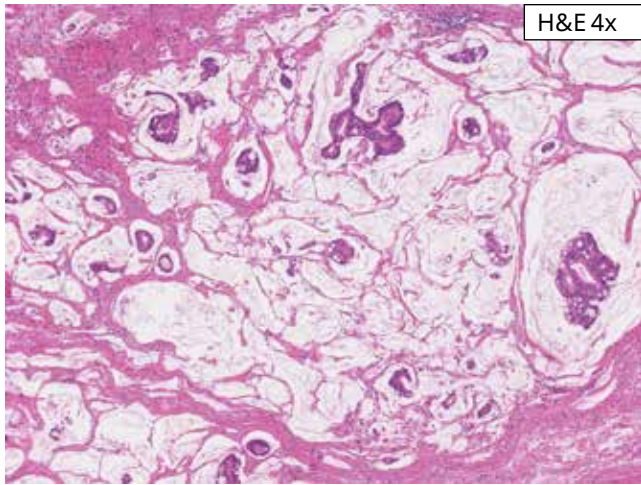
Borderline Case 5: This case exhibits 80% moderate to strong membrane staining in a predominantly circumferential pattern. This case is borderline positive for CLDN18 IHC status.



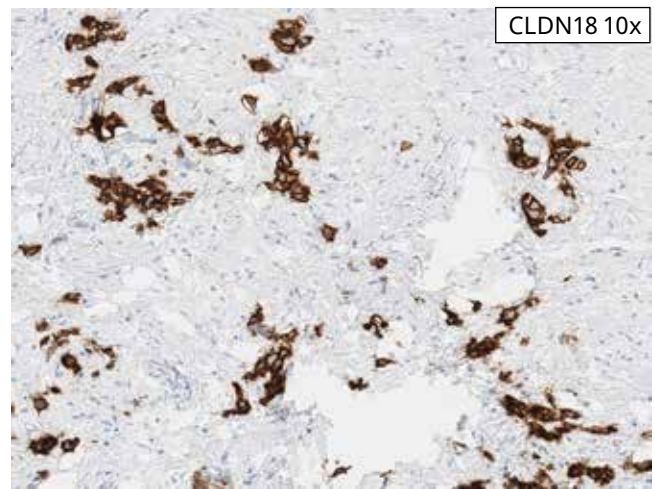
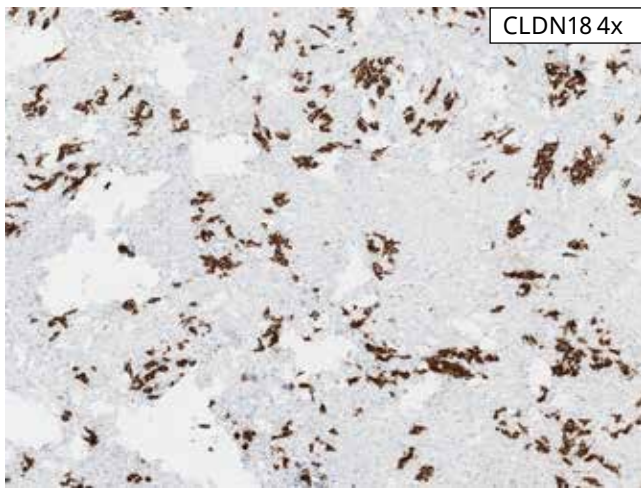
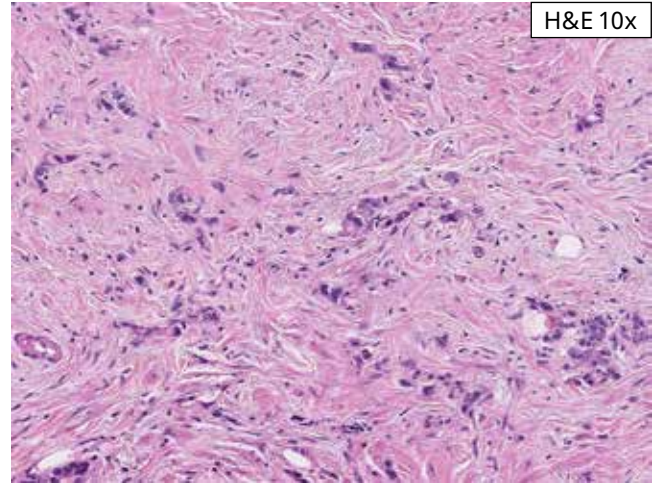
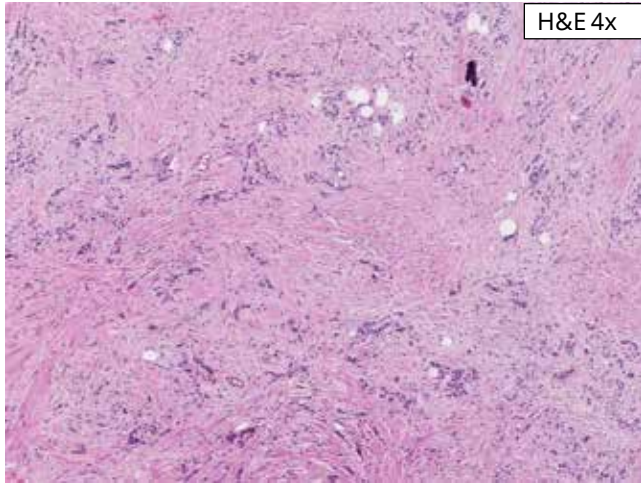
Borderline Case 6: This case of diffusely infiltrative tumor shows partial to complete circumferential membrane staining of moderate to strong intensity in 85% of tumor cells. This case is borderline positive for CLDN18 status.

Positive Cases

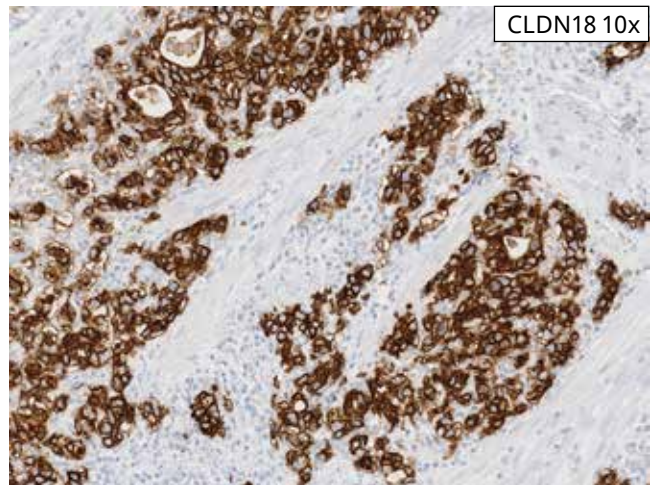
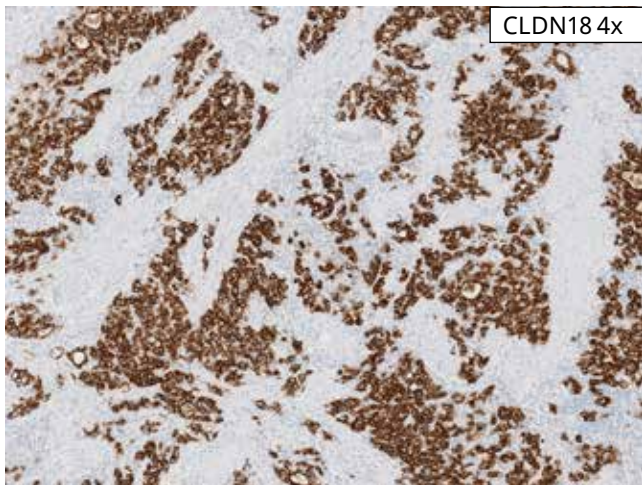
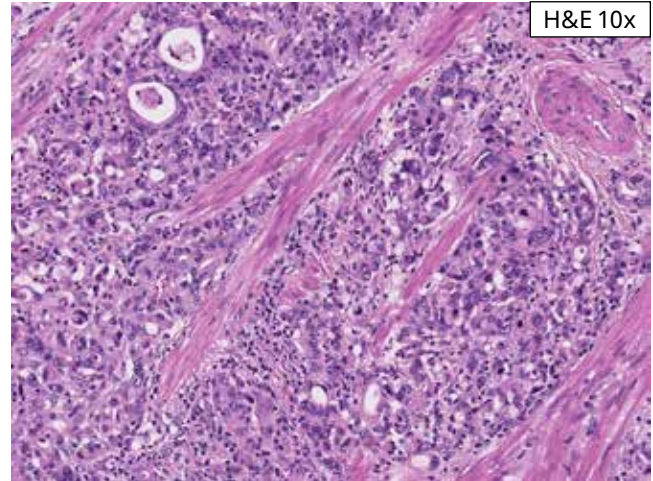
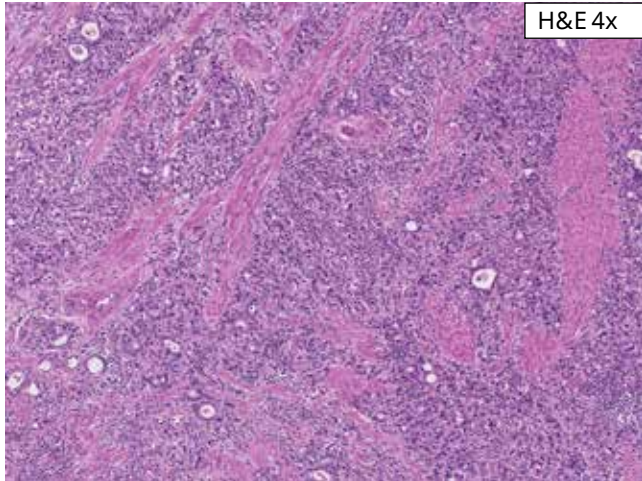
A case with a positive CLDN18 IHC status is characterized by $\geq 75\%$ viable tumor cells demonstrating moderate to strong membrane staining with acceptable background.



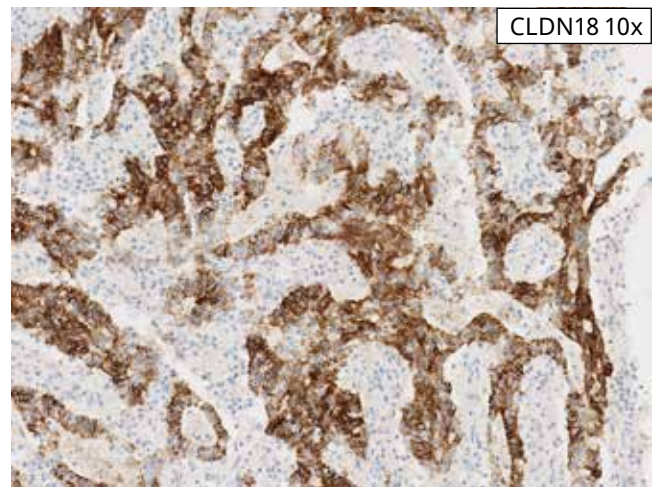
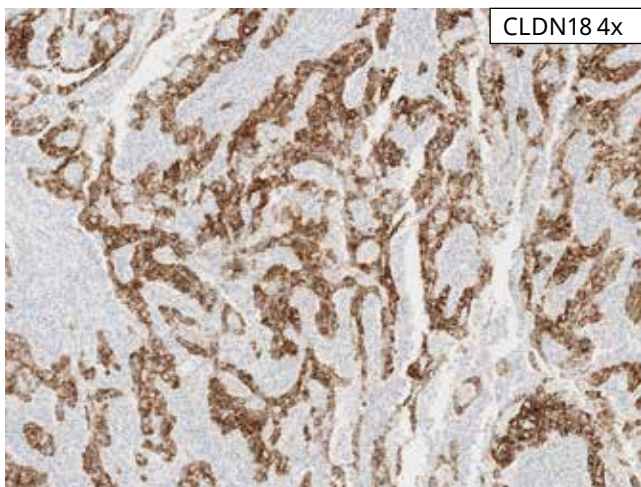
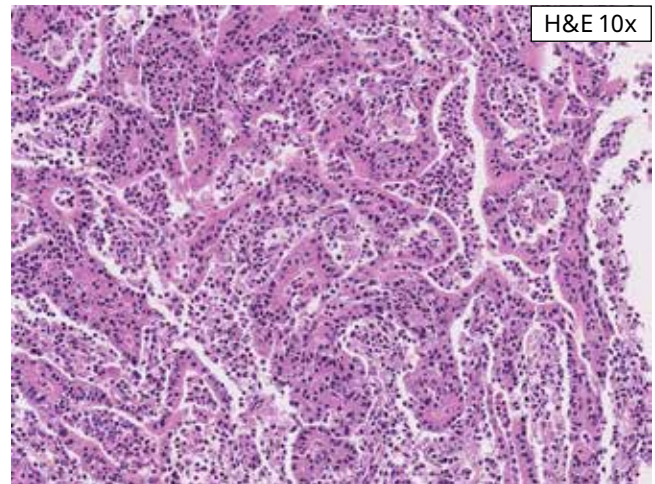
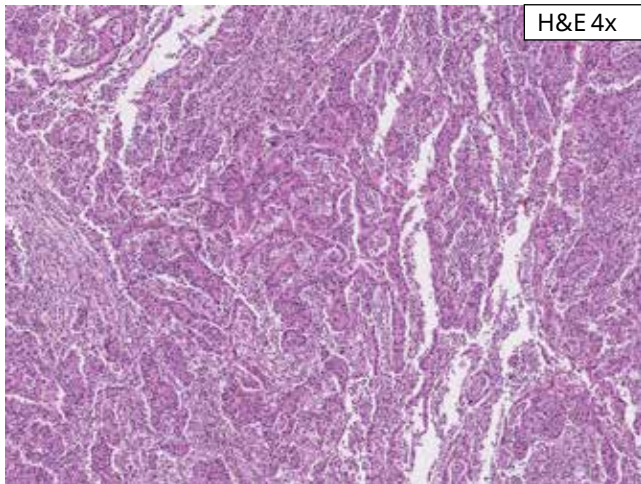
Positive Case 1: This case exhibits moderate to strong membrane staining in 90% of tumor cells. Both circumferential (complete) and apical staining patterns are seen in this mucinous intestinal type carcinoma. This case is positive for CLDN18 IHC status.



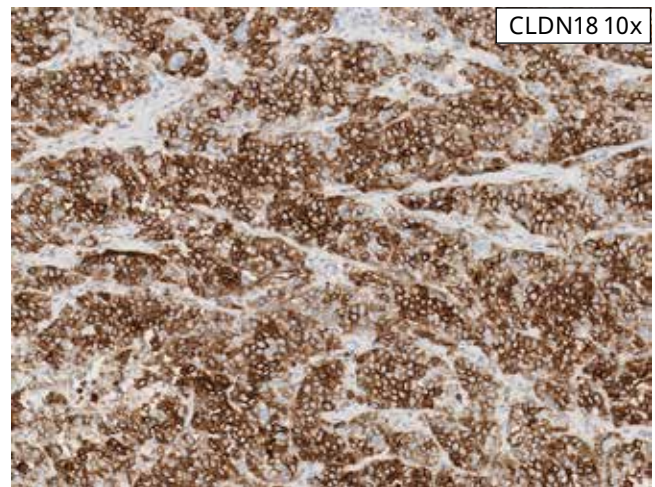
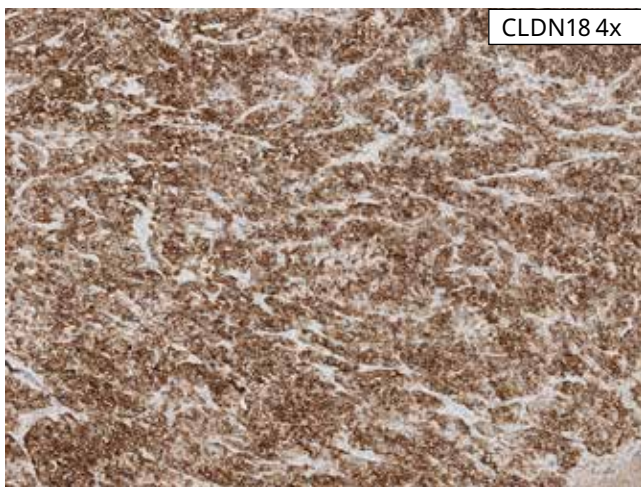
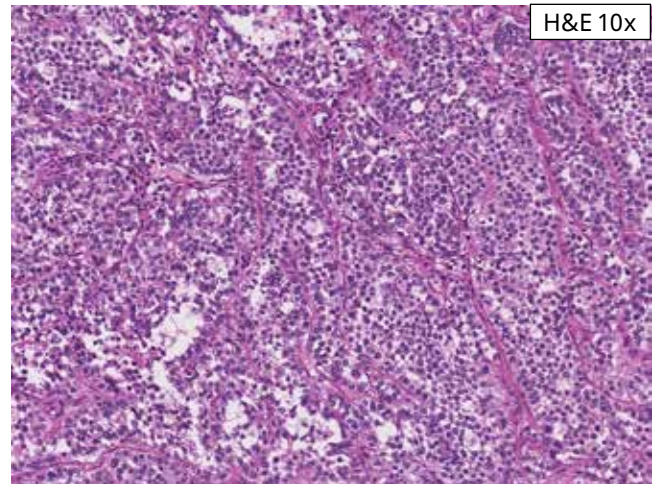
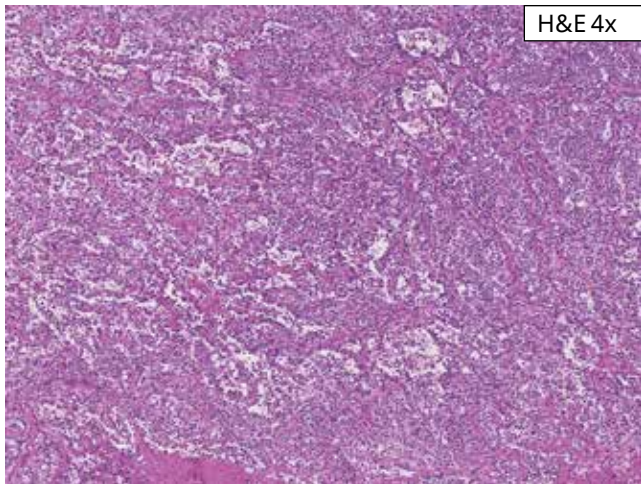
Positive Case 2: This case exhibits moderate to strong membrane staining in 95% of the tumor cells and is positive for CLDN18 IHC status.



Positive Case 3: This case exhibits moderate to strong membrane staining in 95% of tumor cells. This case is positive for CLDN18 IHC status.



Positive Case 4: This case exhibits moderate to strong membrane staining in 95% of tumor cells. This case is positive for CLDN18 IHC status.



Positive Case 5: This case exhibits moderate to strong membrane staining in 100% of tumor cells. This case is positive for CLDN18 IHC status.

Challenging Cases

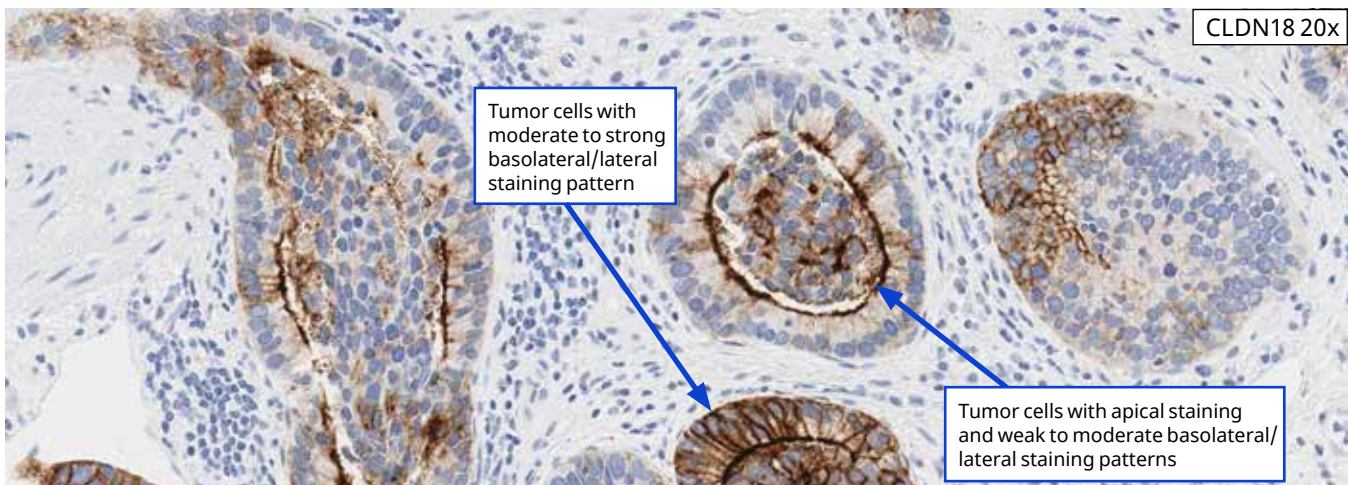
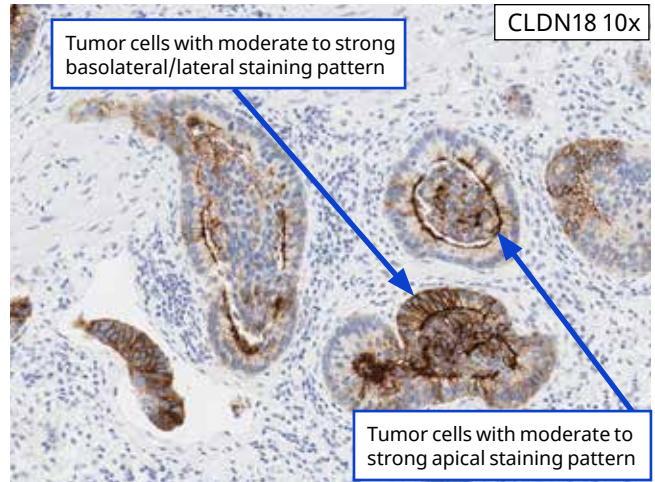
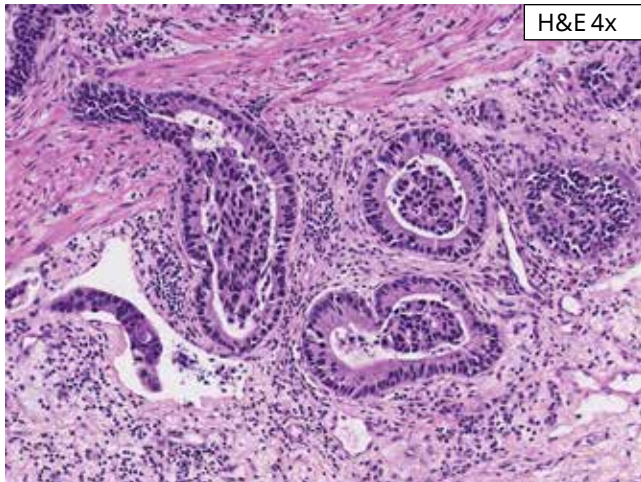
In general, there are two major challenges in scoring CLDN18 in gastric cancer.

Tumor morphology: Usually there is no difficulty in assessing tumors with intestinal type morphology. However, it can be difficult at times to discern infiltrating tumor cells from other cell types if the morphology is diffuse or signet ring cells. Non-specific CLDN18 staining can be seen in mucin and necrosis, which can make interpretation of the CLDN18 IHC assay difficult.

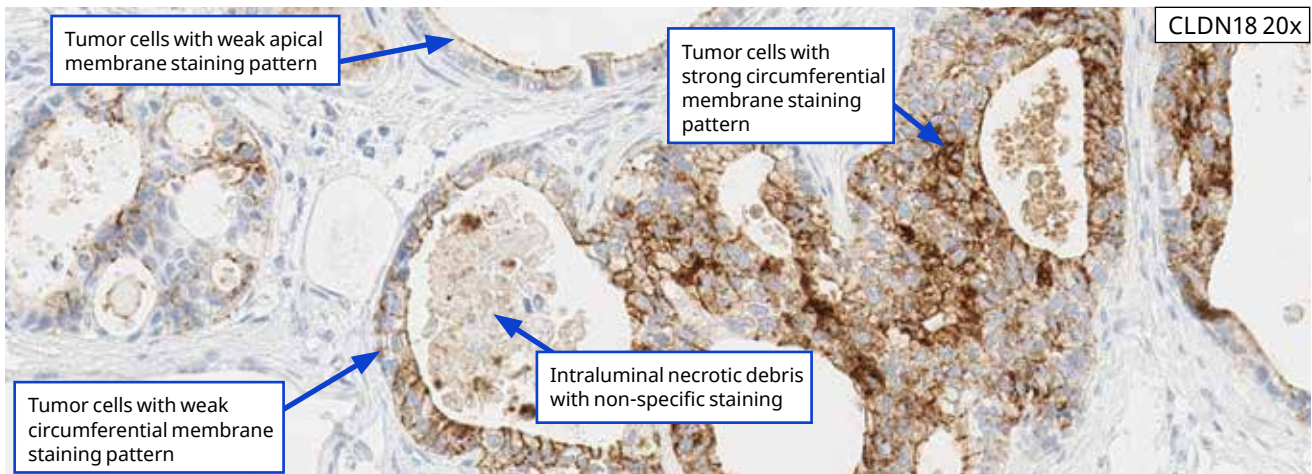
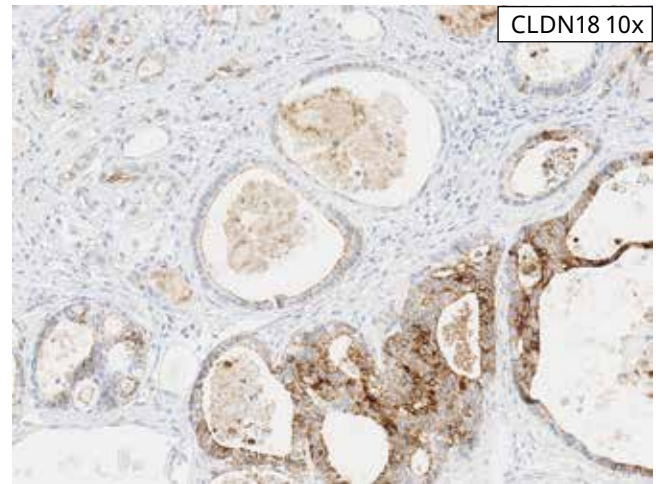
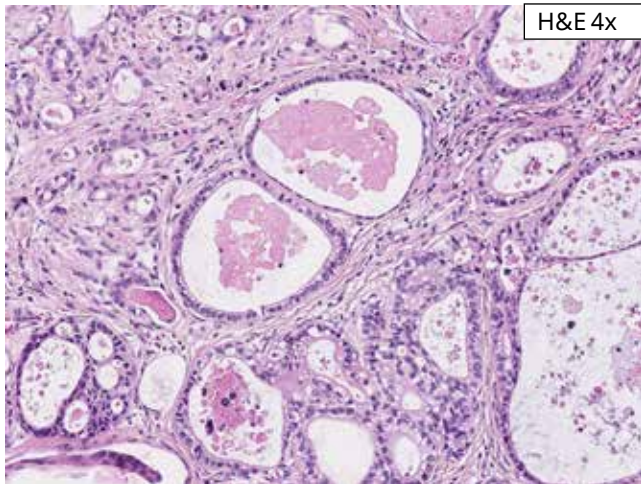
Borderline CLDN18 IHC status: Scoring cases with CLDN18 staining that are at or near the 75% cut-off. While the vast majority of cases stained with VENTANA CLDN18 (43-14A) RxDx Assay are clearly positive or negative in their staining results, some cases have been observed that present a challenge in interpretation.

Following are some images which may prove useful in scoring challenging cases.

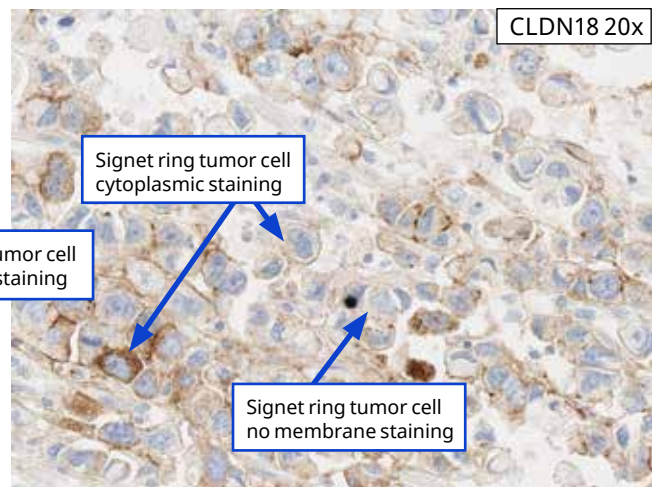
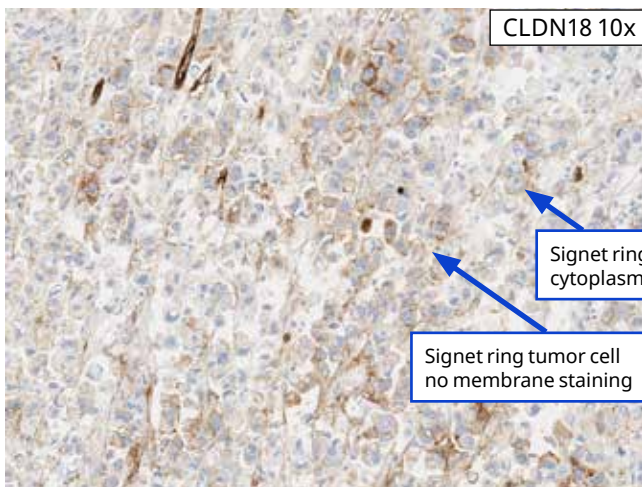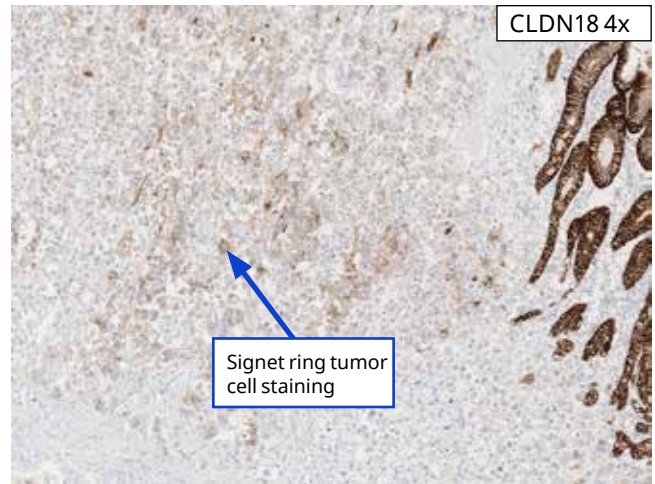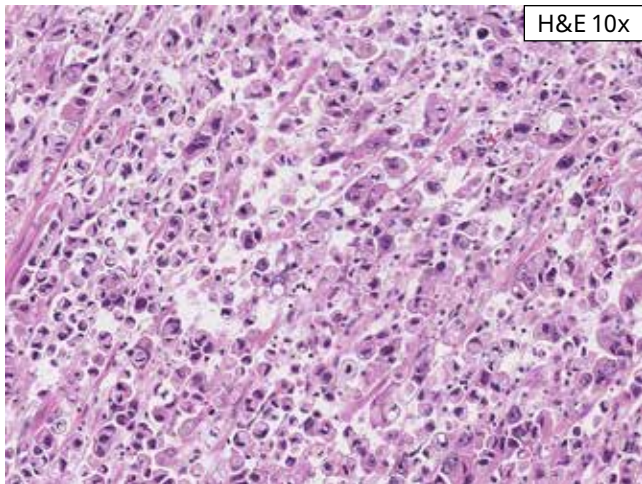
Tumor cell membrane staining can be circumferential (partial or complete), apical, or less commonly basolateral/lateral. Often the apical and circumferential patterns are seen together. When more than one staining pattern is present, score the stronger intensity for that tumor cell. For example, if there is strong apical staining in a gland and weak circumferential or basolateral/lateral staining, score those tumor cells as having strong staining.



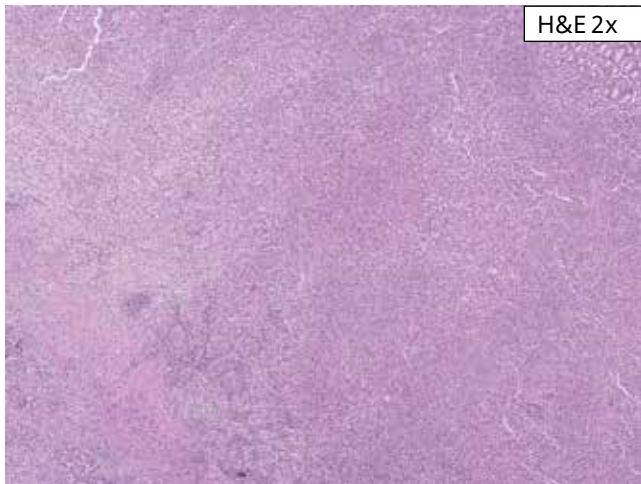
Challenging Case 1: This case with intestinal morphology shows strong basolateral/lateral and apical pattern staining in 90% tumor cells. Weak to moderate basolateral/lateral membrane staining is also present. In this gland, essentially all the tumor cells show strong apical staining and would count toward percent tumor cell positivity. Always score tumor cells at the strongest membrane intensity. This case is positive for CLDN18 IHC status.



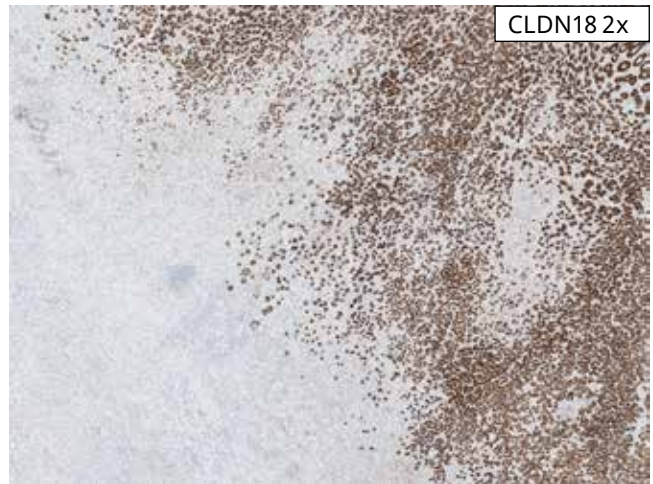Challenging Case 2: This case exhibits intestinal type morphology, with heterogeneous staining intensities. Apical and circumferential tumor cell membrane staining patterns are present. Also, gland size variation is present, which can make estimation of number of tumor cells difficult. Non-specific staining of intraluminal necrotic debris is also present. Moderate to strong membrane staining is assessed at 55% for this case. This case is negative for CLDN18 IHC status.



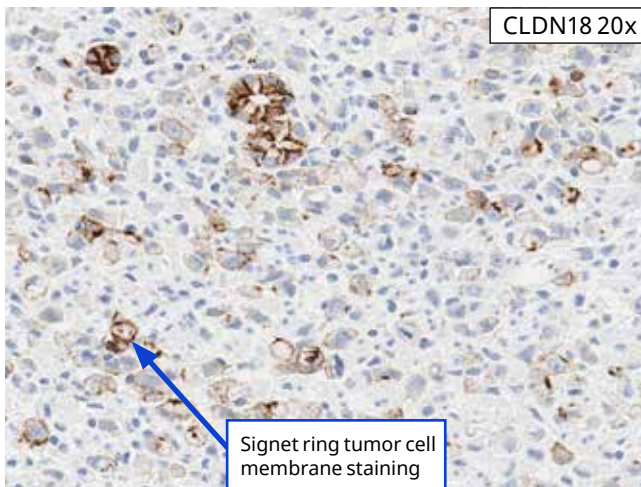
Challenging Case 3: This case exhibits infiltrating signet ring tumor cells within the mucosa along with immune infiltrate between non-neoplastic glands. Strong membrane staining is present in 30% of tumor cells. In the lower images, some signet ring cells show no staining and some show cytoplasmic and/or membrane staining. This case is negative for CLDN18 IHC status.



H&E 2x

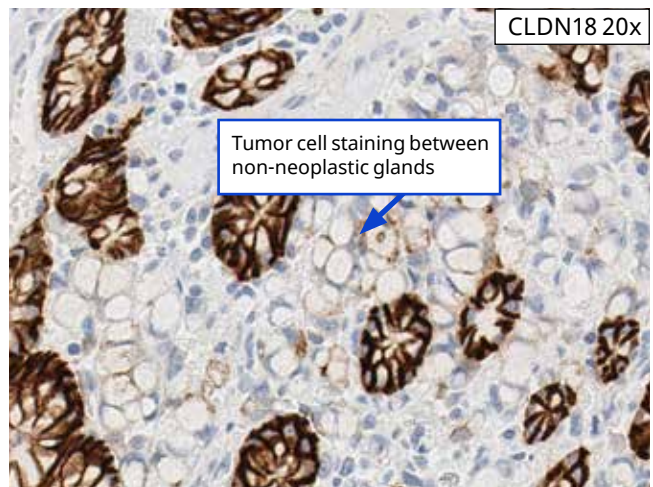


CLDN18 2x



CLDN18 20x

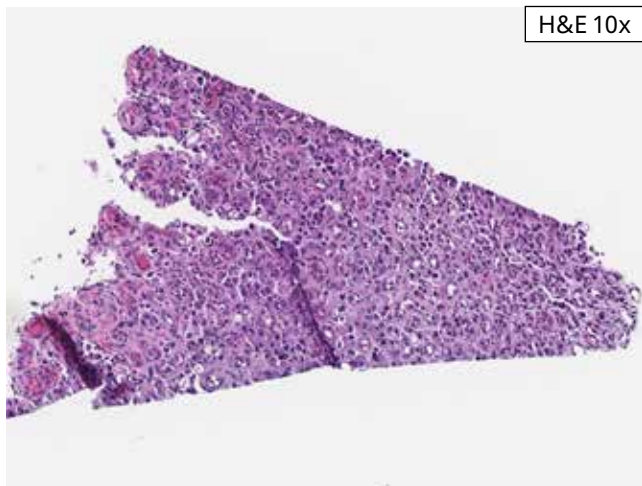
Signet ring tumor cell membrane staining



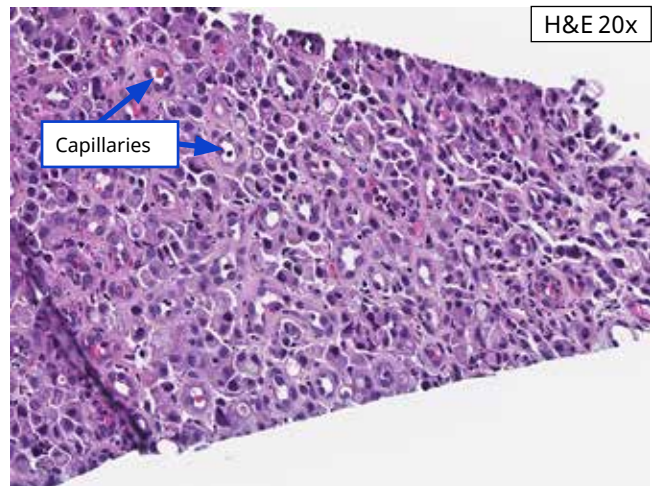
CLDN18 20x

Tumor cell staining between non-neoplastic glands

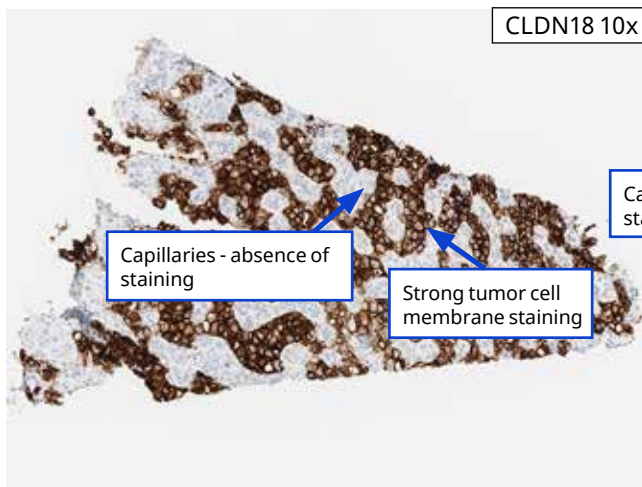
Challenging Case 4: This case exhibits signet ring cell morphology. Majority of tumor cells show no staining (20x), but a few scattered tumor cells show membrane staining deeper in the tumor (left image) along with tumor cell staining between non-neoplastic glands (right image). This case shows 10% tumor cell staining. This case is negative for CLDN18 IHC status.



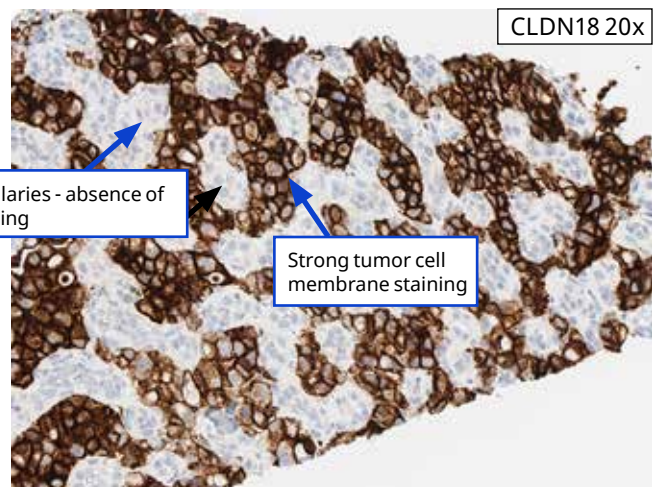
H&E 10x



H&E 20x

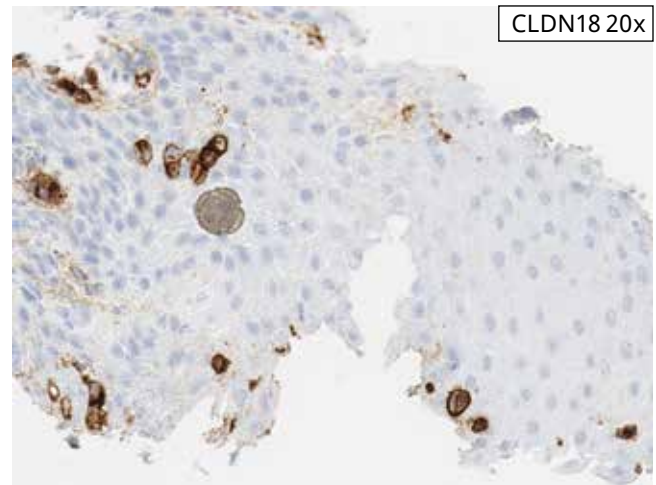
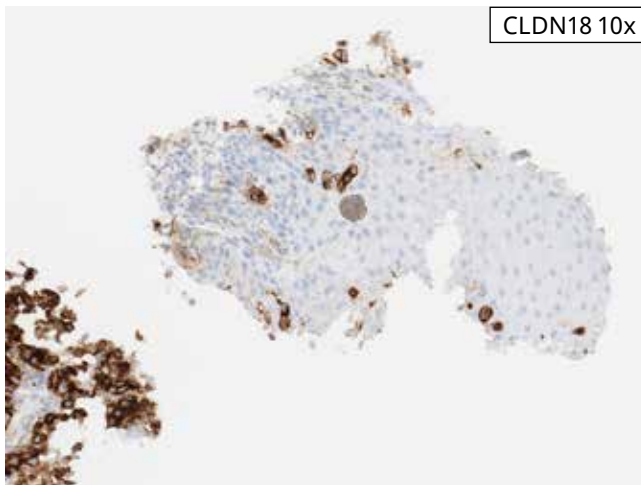
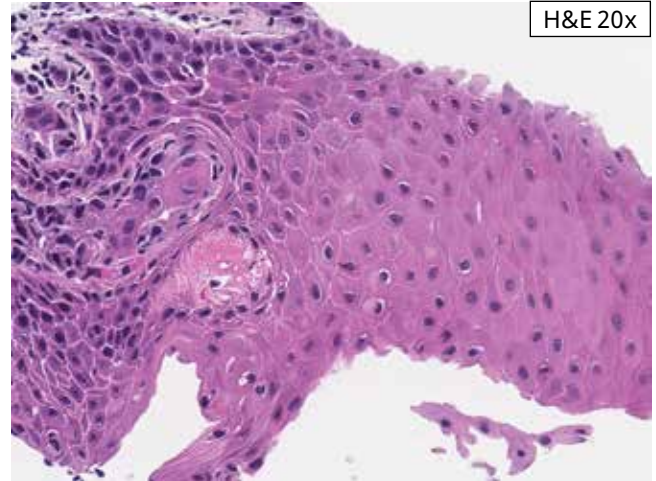
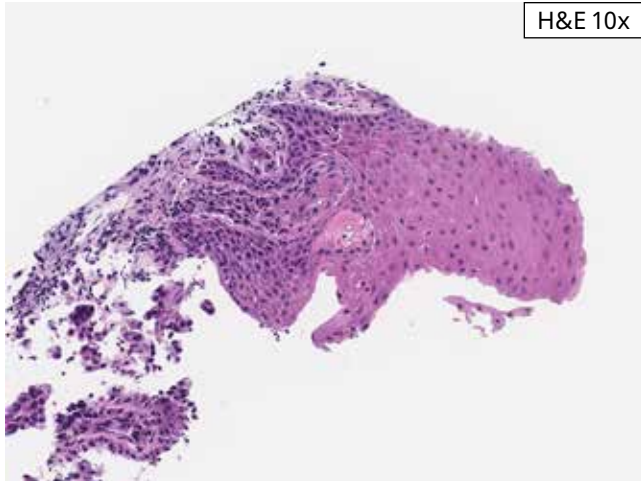


CLDN18 10x

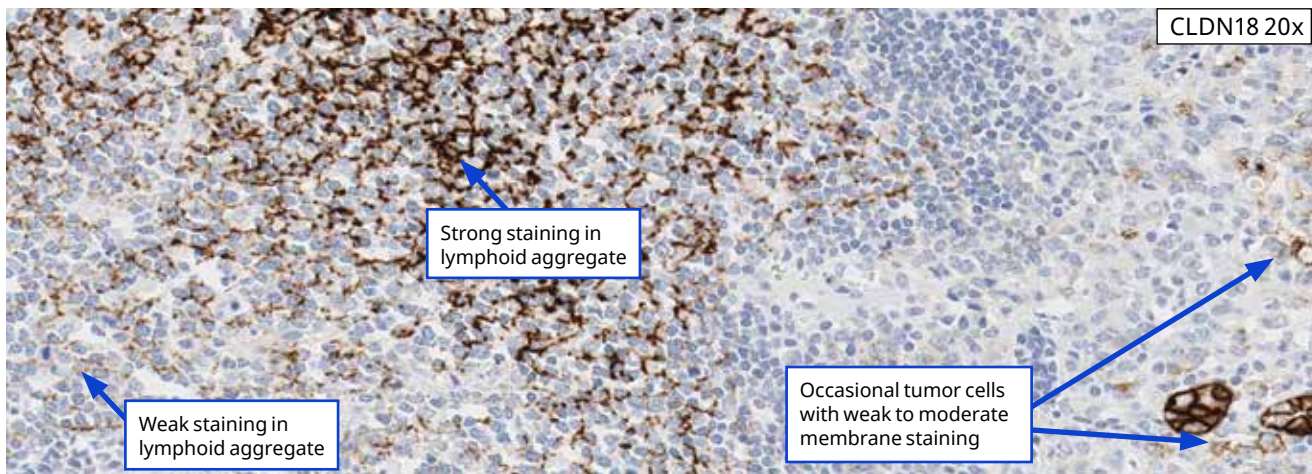
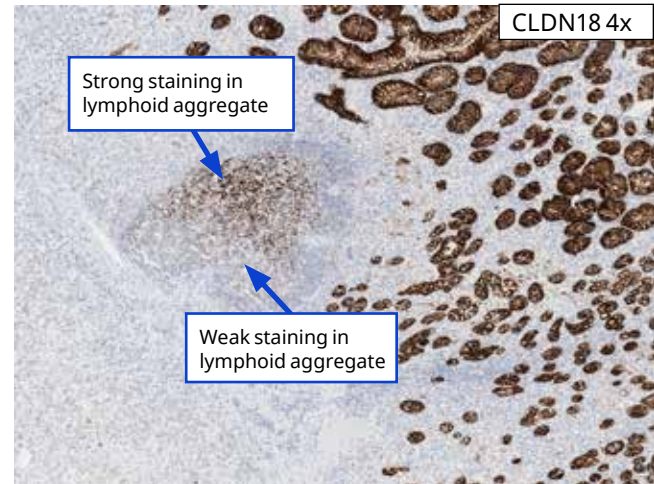
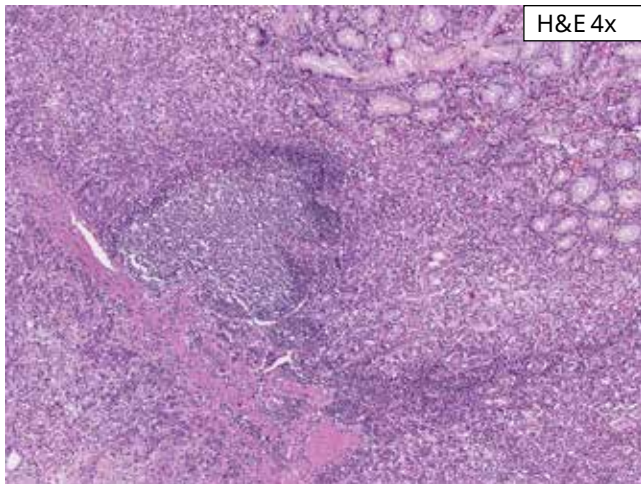


CLDN18 20x

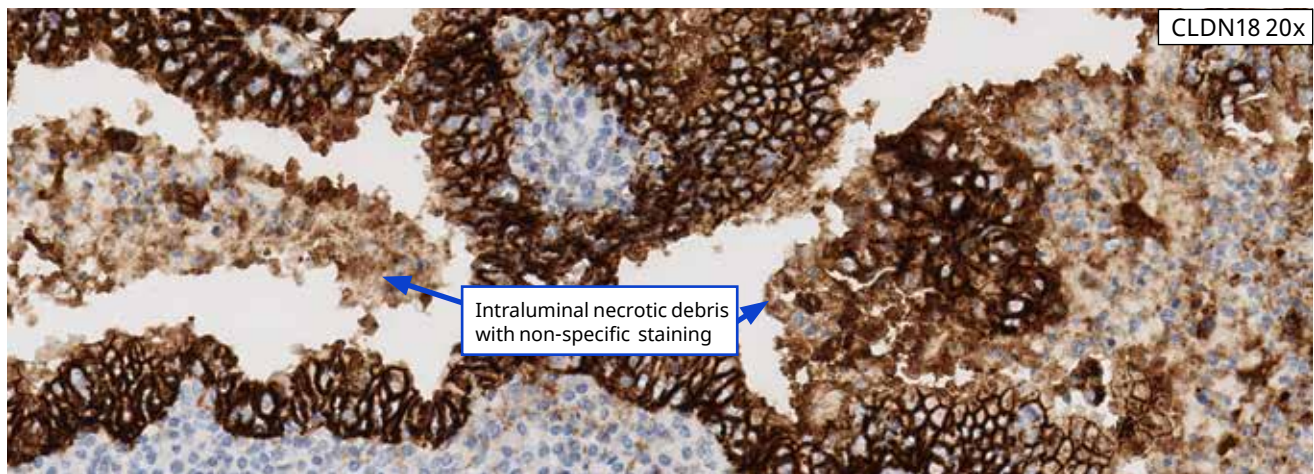
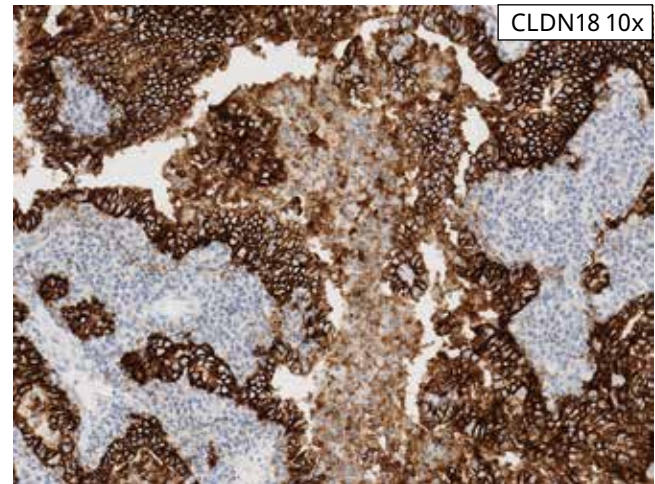
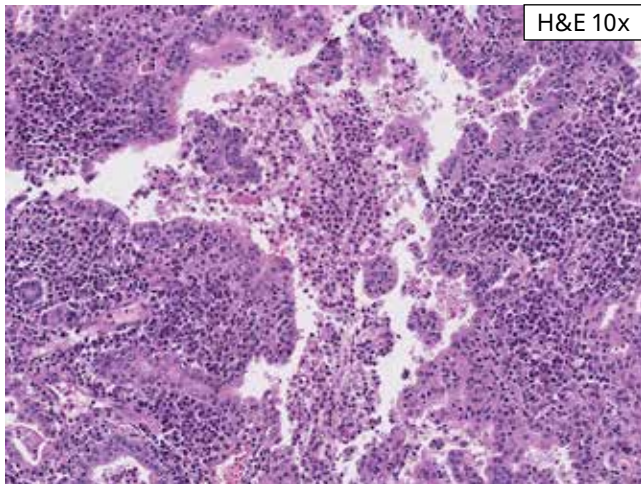
Challenging Case 5: This case exhibits strong tumor cell membrane staining and an absence of staining in capillaries lined by prominent endothelial cells. For such cases, it is recommended to refer back to the H&E slide and to examine the CLDN18-stained slide at higher magnification. This case shows 85% tumor cell staining and is borderline positive for CLDN18 IHC status.



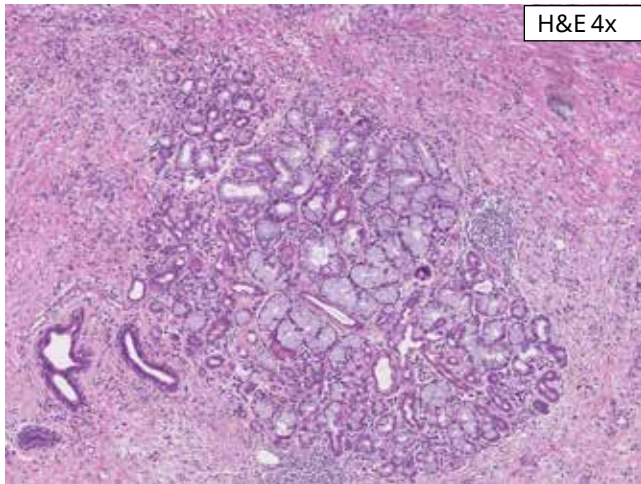
Challenging Case 6: This case exhibits strong membrane staining in cells that appear to be within the squamous epithelium. Do not score cells in squamous epithelium unless confident that these are tumor cells (within the vascular papillae or show pagetoid spread). This case shows 95% moderate to strong tumor cell staining. This case is positive for CLDN18 IHC status.



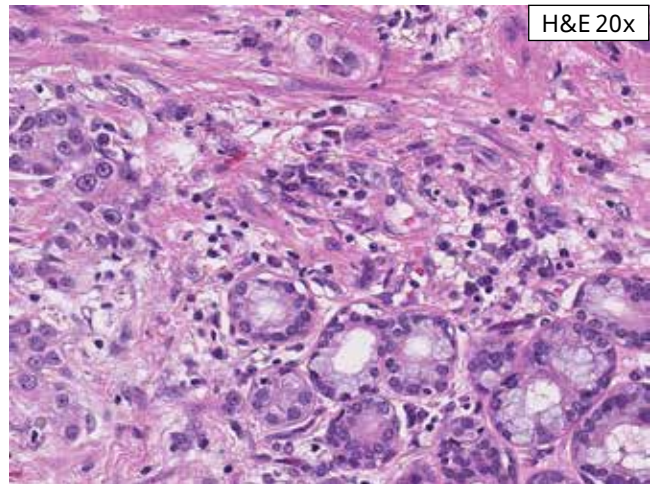
Challenging Case 7: A prominent lymphoid aggregate with a germinal center is seen in this case. At 4x (upper right), it appears that non-neoplastic glands are showing strong membrane staining and staining is present within the lymphoid aggregate. At 20x (bottom), it is apparent that weak to strong staining is seen within the associated dendritic cell processes. This histologic feature may be seen on occasion and should not be confused with tumor cell membrane staining. Tumor with little weak to moderate membrane staining is seen encroaching upon the lymphoid aggregate in the right portion of the image. Entrapped non-neoplastic glands with strong membrane staining are also present. This case exhibits moderate to strong membrane staining in 15% of tumor cells and is negative for CLDN18 IHC status.



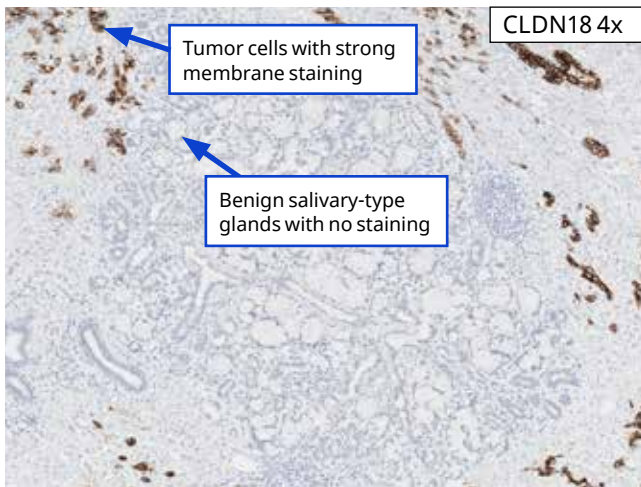
Challenging Case 8: This case exhibits non-specific staining of necrotic tissue. Non-viable tumor cells within necrotic debris should be excluded from total percent tumor cell staining. The tumor cells lining of the gland show strong membrane staining. This case is assessed at 100% moderate to strong tumor cell membrane staining and is positive for CLDN18 IHC status.



H&E 4x



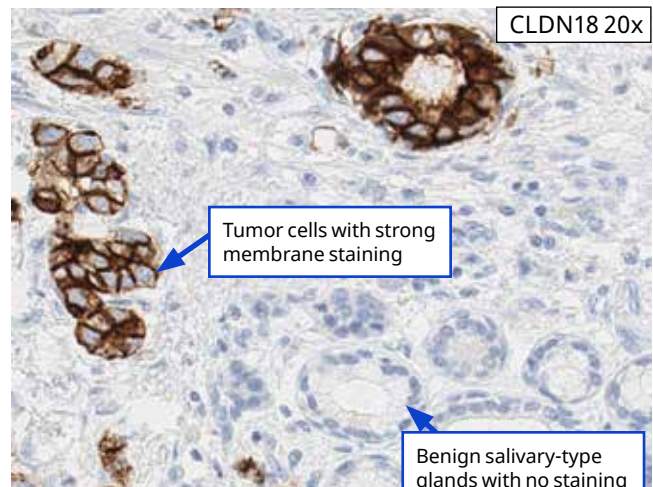
H&E 20x



CLDN18 4x

Tumor cells with strong membrane staining

Benign salivary-type glands with no staining

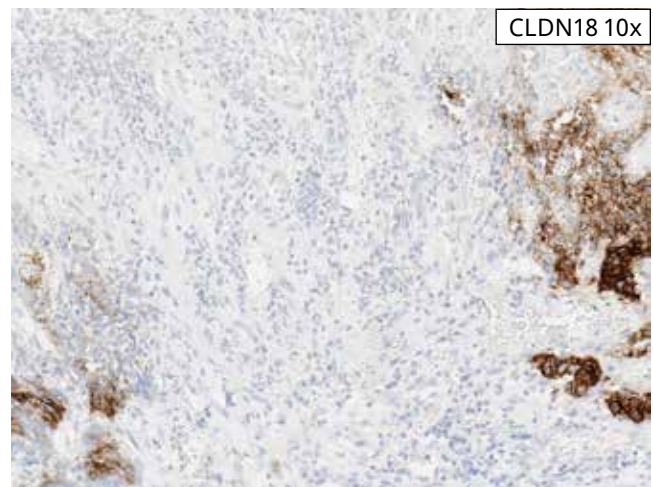
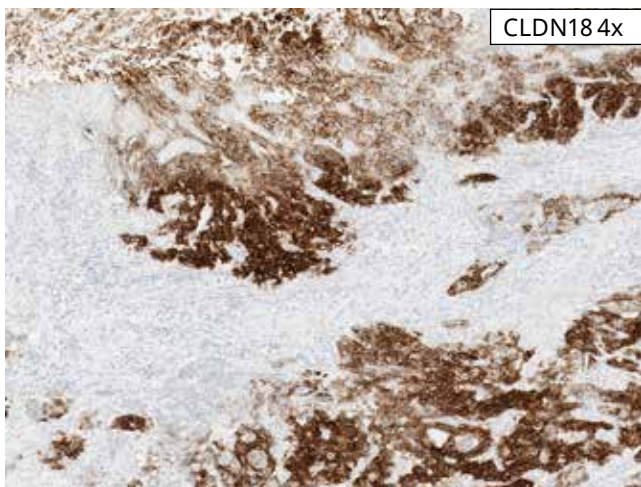
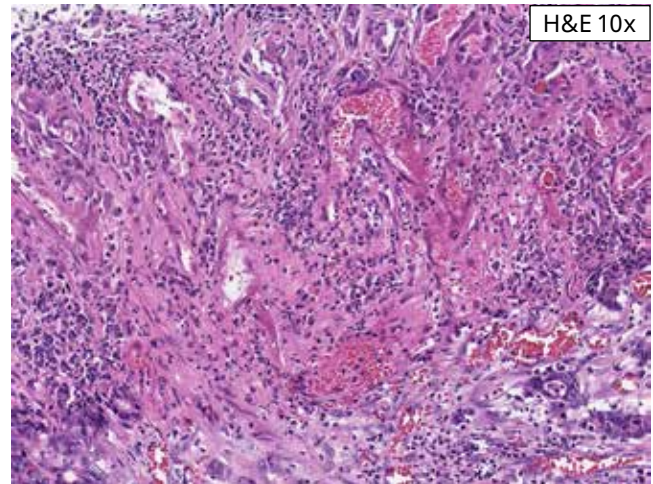
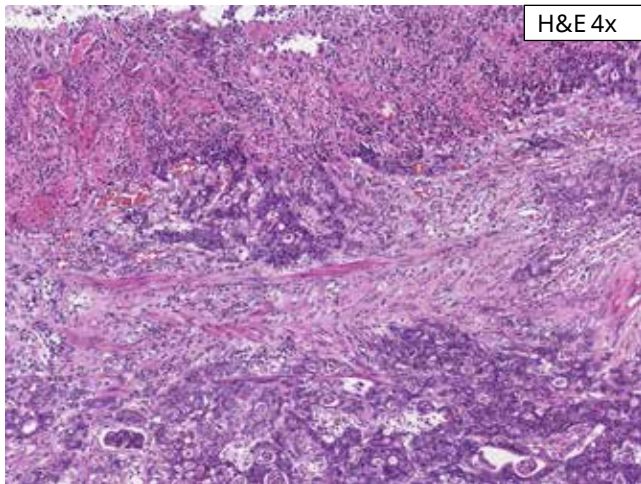


CLDN18 20x

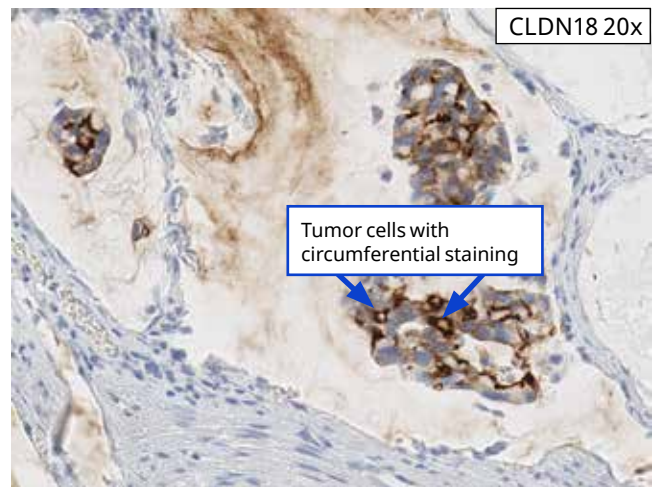
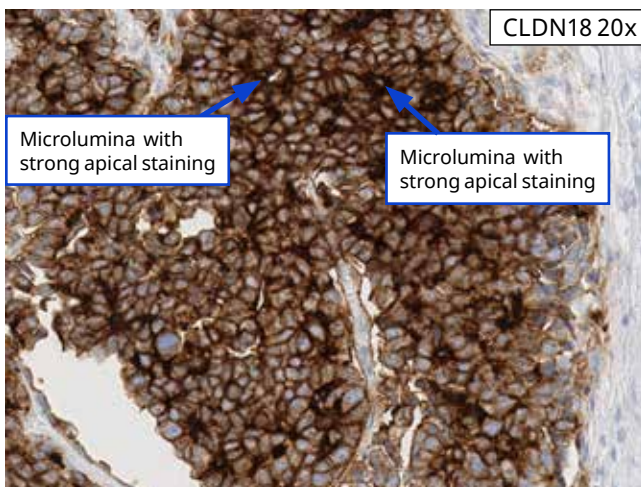
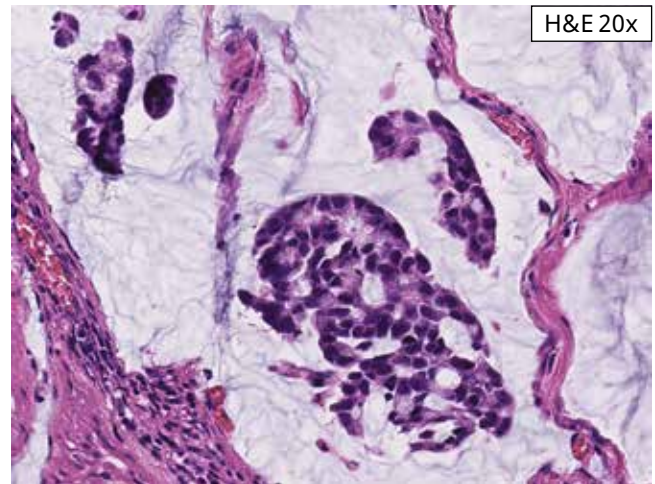
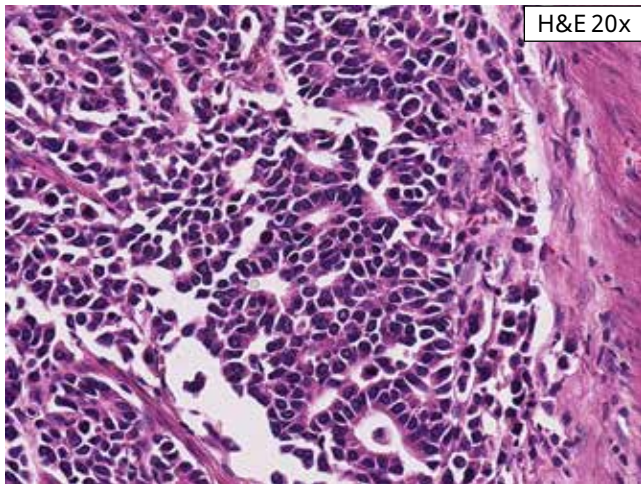
Tumor cells with strong membrane staining

Benign salivary-type glands with no staining

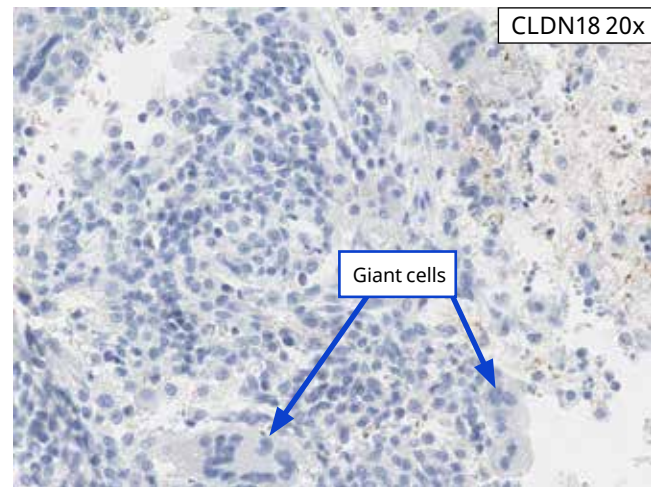
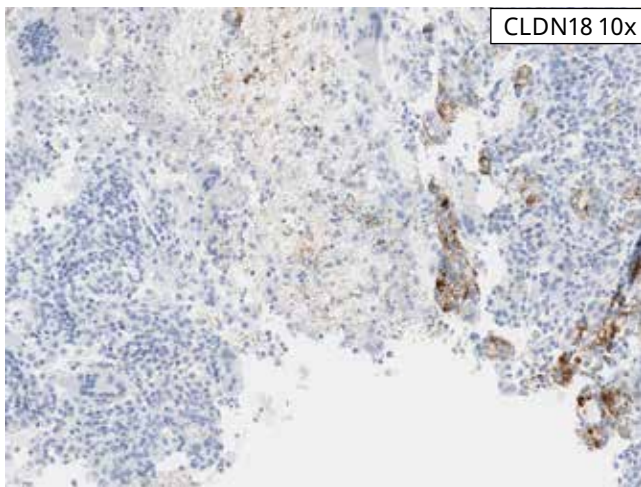
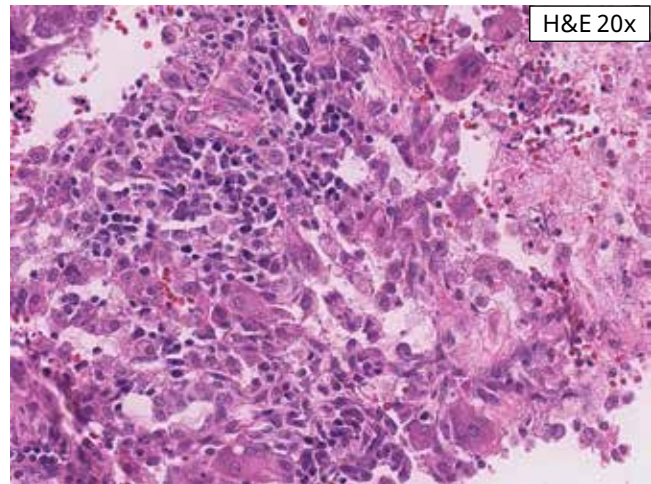
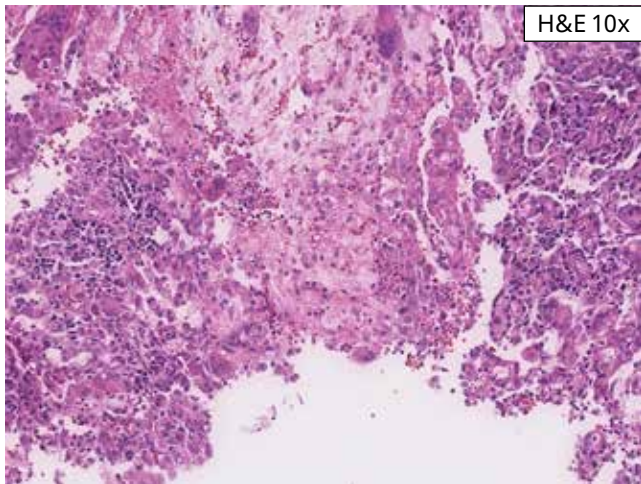
Challenging Case 9: This case exhibits benign salivary-type glands, which are often seen in the lower esophagus/GEJ and show no CLDN18 staining. Adjacent tumor cells show strong membrane staining in 100% of tumor cells. Be careful not to include the non-tumor cells, as this may impact the assessment of percent tumor cell membrane staining. This case is positive for CLDN18 IHC status.



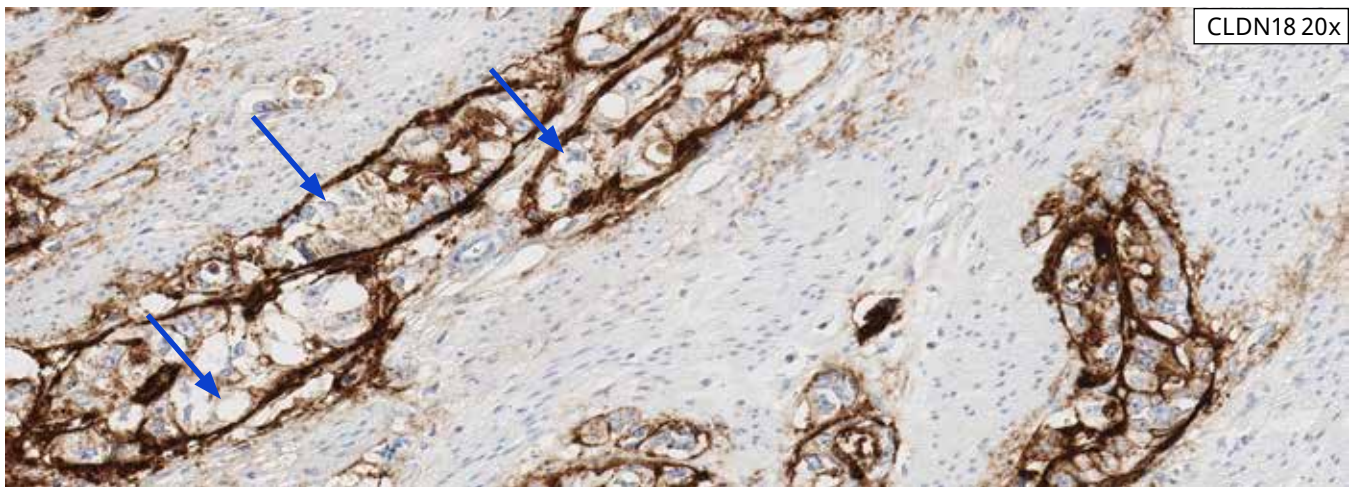
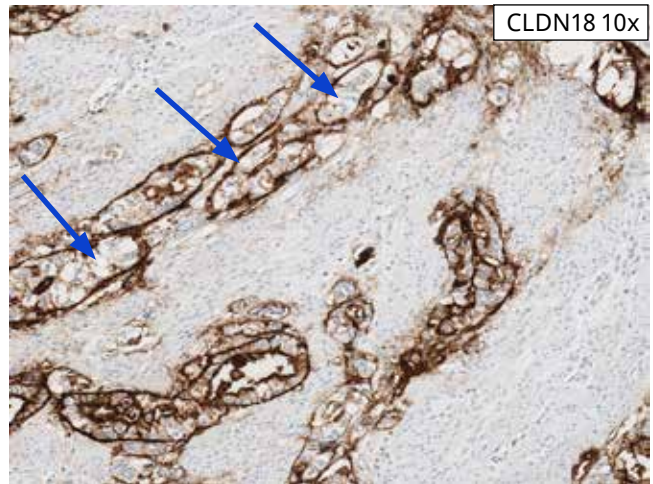
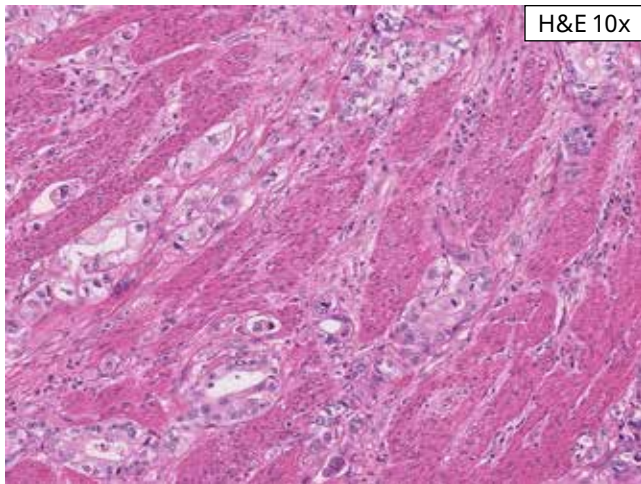
Challenging Case 10: The majority of gastric cancers ulcerate. Careful examination of the ulcer bed on H&E is required to avoid including negative reactive endothelial and/or stromal cells as negative staining tumor cells, potentially resulting in a false negative IHC case status or excluding negative tumor cells as negative staining ulcer bed, potentially resulting in a false positive IHC case status. This case is assessed as 90% positive for moderate to strong tumor cell staining and is positive for CLDN18 IHC status.



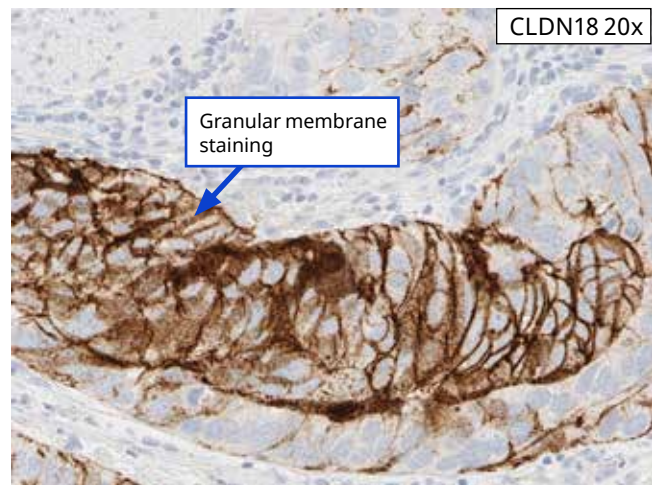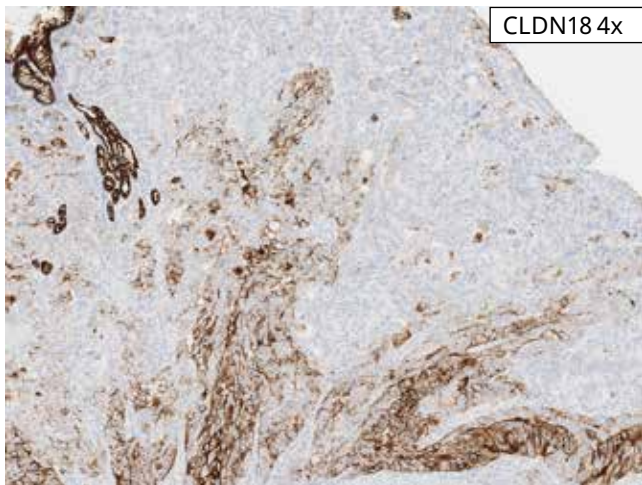
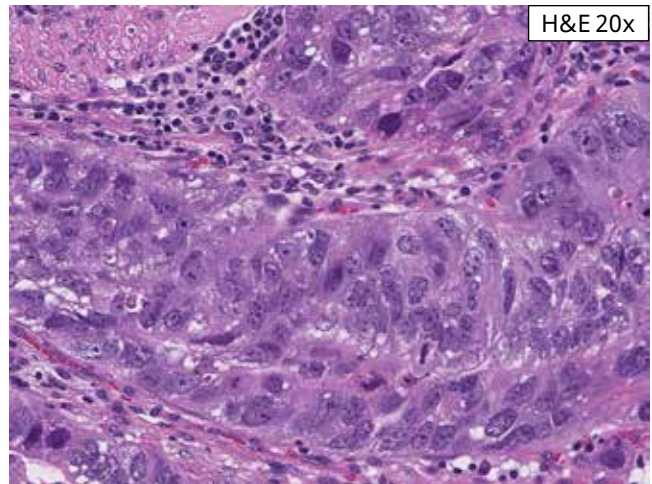
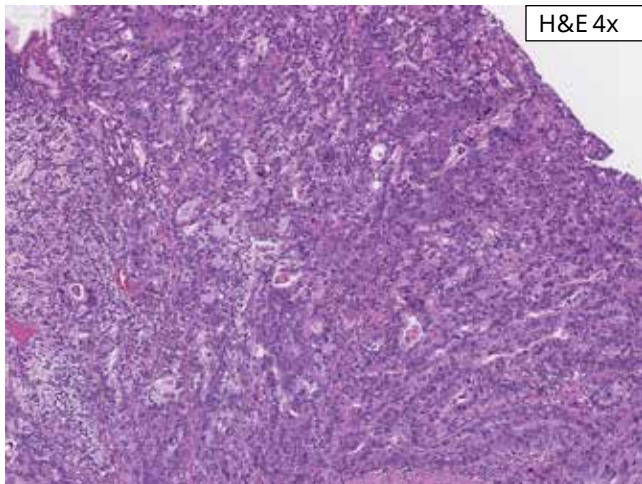
Challenging Case 11: The above case shows intestinal morphology with areas of obvious gland formation, focal mucinous morphology with clusters of coherent tumor cells floating in mucin pools, and focal more solid areas. The CLDN18-stained tumor in the lower left panel (20x) shows circumferential tumor cell staining. In addition, in areas of gland formation, microlumina formation is seen with strong apical staining. Sometimes, the lumina can easily be seen, but often are not. If this staining pattern is seen with moderate to strong intensity, all tumor cells sharing this unusual apical staining pattern are counted toward percent tumor cell positivity. This case shows 80% moderate to strong tumor cell staining and is borderline positive for CLDN18 IHC status.



Challenging Case 12: This case of gastric adenocarcinoma shows ulceration, common in gastric adenocarcinoma. In this case, foreign body giant cells are seen in association with the area of ulceration. Like tissue macrophages, foreign body giant cells show no staining (as seen in the CLDN18-stained tissue on the right). Foreign body giant cells should not be counted as viable tumor. This case is scored at 70% moderate to strong tumor cell staining and is borderline negative for CLDN18 IHC status.



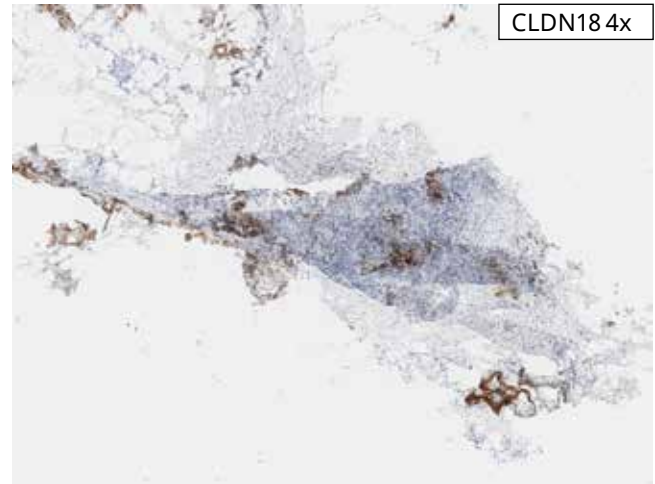
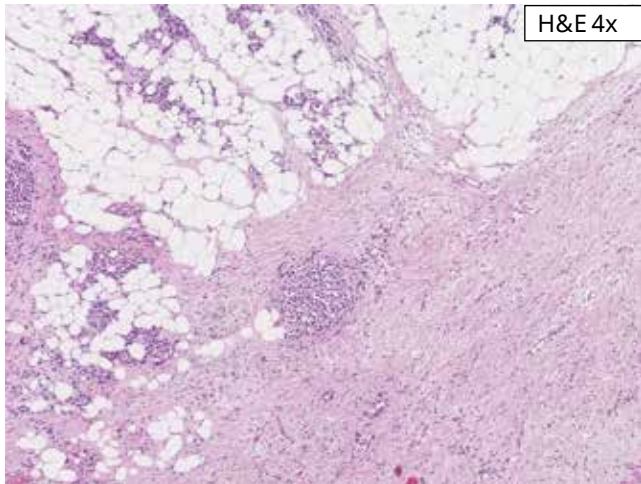
Challenging Case 13: This case of gastric adenocarcinoma shows strong basement membrane staining of most of the malignant glands. Strong apical staining and weak to moderate lateral staining is also present. Tumor cells which show moderate to strong membrane staining in apical, circumferential (partial or complete), and/or basolateral/lateral staining patterns are scored and counted toward percent positive tumor cells. Tumor cells which show moderate to strong basement membrane staining but none of the other membrane staining patterns are not counted toward percent CLDN18 positive tumor cells. This case shows 50% moderate to strong tumor cell staining and is negative for CLDN18 IHC status.



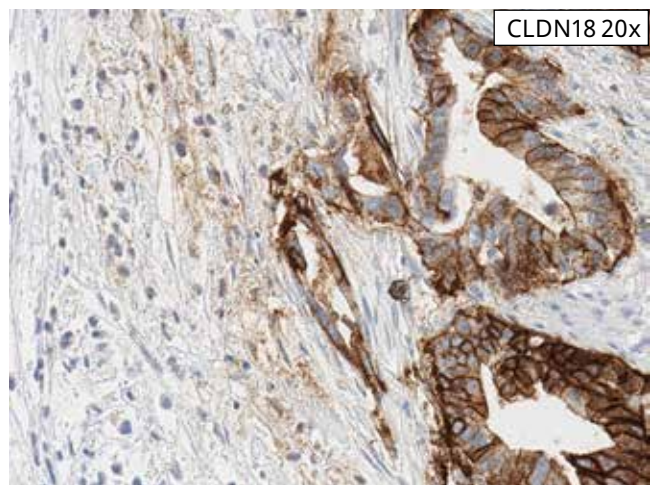
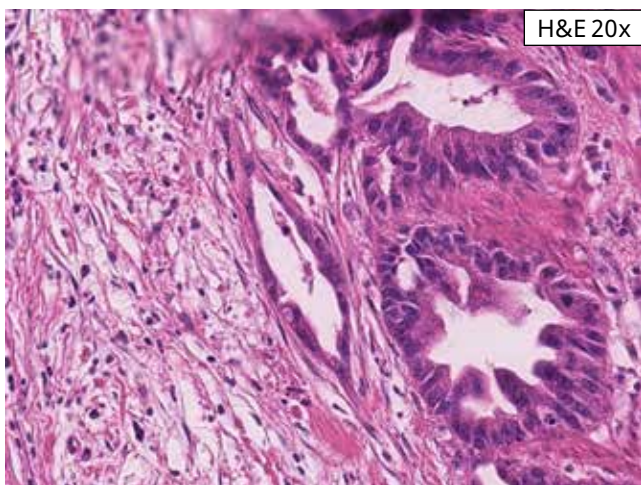
Challenging Case 14: This case demonstrates both mostly strong linear membrane staining (right area of large tumor nest) and granular membrane staining in 50% tumor cells. Granular or punctate membrane staining is often seen with granular cytoplasmic staining. Granular membrane staining is counted towards percent tumor cell positivity if moderate to strong and aligned along the tumor cell membrane. This case is negative for CLDN18 IHC status.

Artifacts

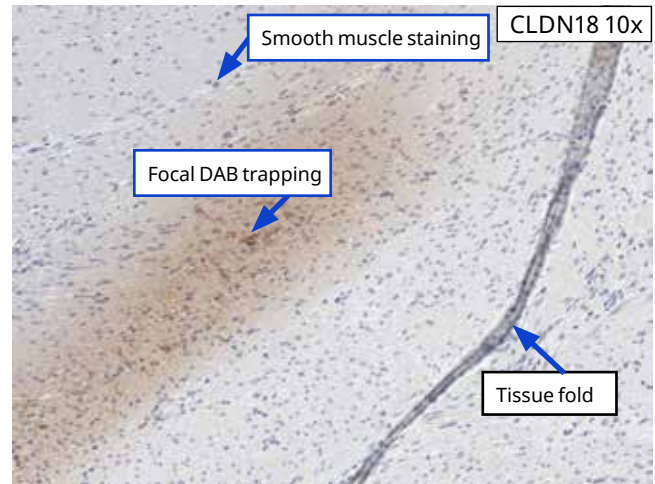
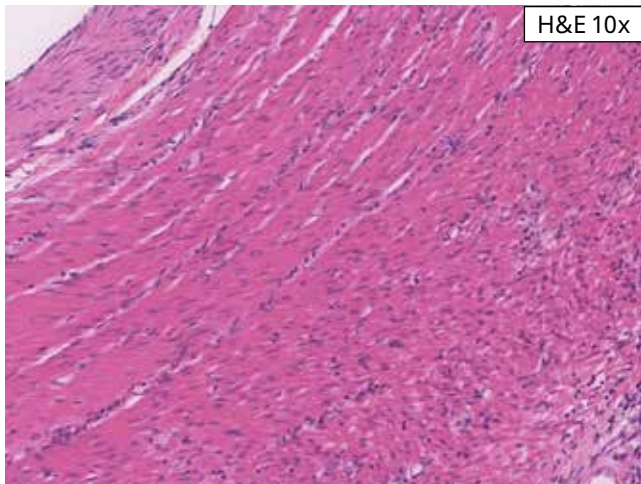
Occasionally, endogenous pigment, melanin or hemosiderin, is present which may mimic DAB staining. In these cases, careful comparison to the patient's negative control (NRC) slide should be helpful in determining endogenous pigment versus true DAB staining. In addition, histologic artifacts originating from the sample processing and microtomy processes can also complicate the determination of the CLDN18 IHC status. These artifacts may include, but are not limited to, fixation gradients, edge effects, DAB trapping, coverslip errors, lack of staining in some regions of the tissue, light spots, tearing or folding of the tissue, and loss of the tissue section. In some instances, repeat staining of new sections or acquisition of a new specimen may be required.



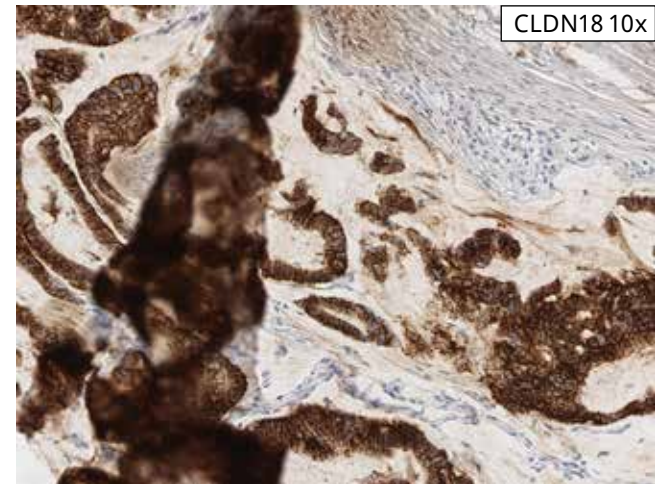
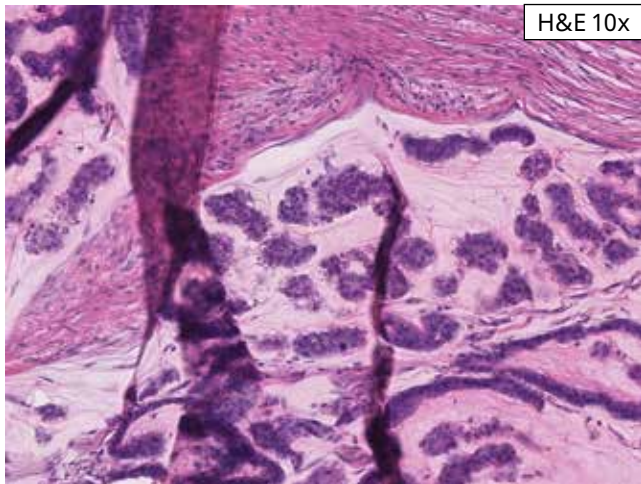
Artifact Case 1: This case shows tissue tearing and folding in the CLDN18-stained slide. The VENTANA CLDN18 (43-14A) RxDx Assay should be repeated in this case. If tissue folding and/or tearing results in the loss of more than 50% of the tumor, or if there are less than 50 viable tumor cells, the assay cannot be interpreted and repeat testing is necessary.



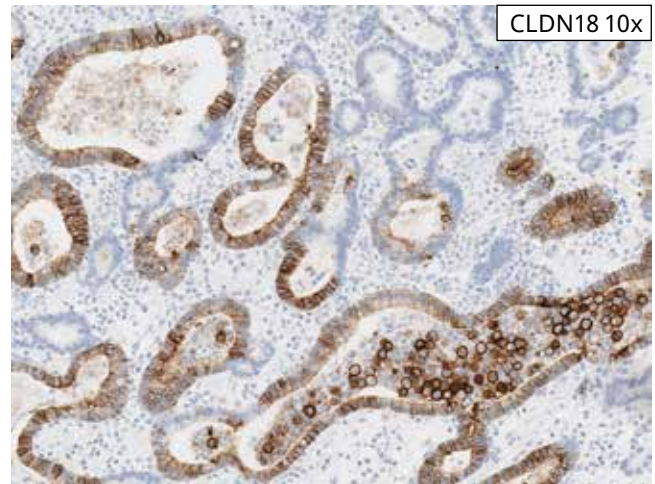
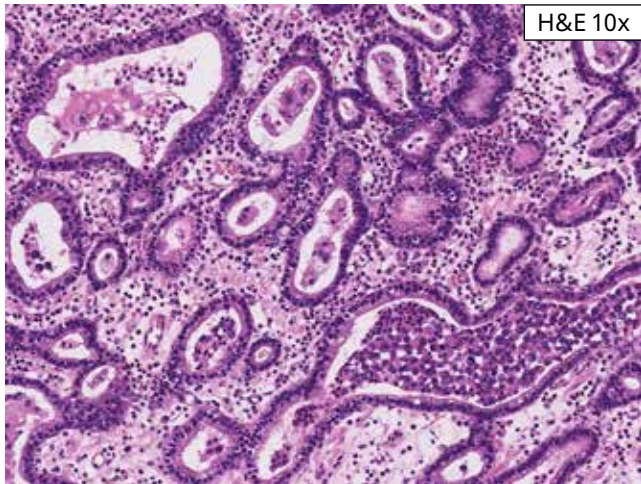
Artifact Case 2: Malignant gastric adenocarcinoma is seen in association with a loose stroma in the H&E image on the left. Some stromal staining is seen in the CLDN18-stained tissue on the right. Minimal stromal staining is occasionally seen and is usually near malignant glands. It usually does not interfere with interpretation of the VENTANA CLDN18 (43-14A) RxDx Assay.



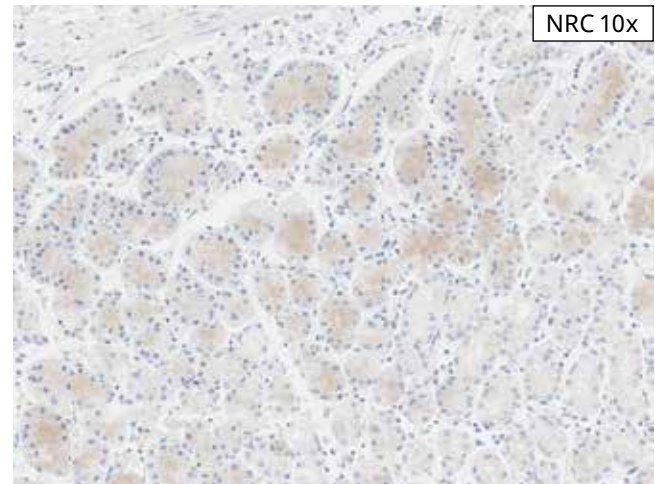
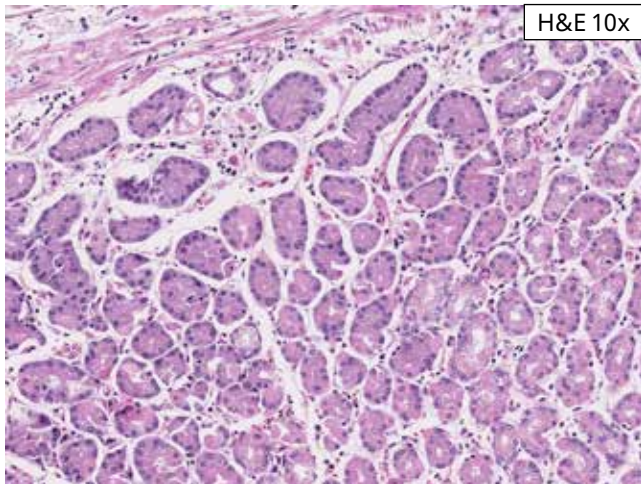
Artifact Case 3: The H&E image on the left shows largely smooth muscle. The CLDN18-stained tissue on the right shows three artifacts. The first is focal DAB trapping. The second is a bluish-like staining of smooth muscle. These artifacts are occasionally seen and should not interfere with the interpretation of the VENTANA CLDN18 (43-14A) RxDx Assay. The third artifact is a tissue fold. Tumor in the area of tissue folding should not be scored, as the overlapping of tissue can intensify the CLDN18 staining.



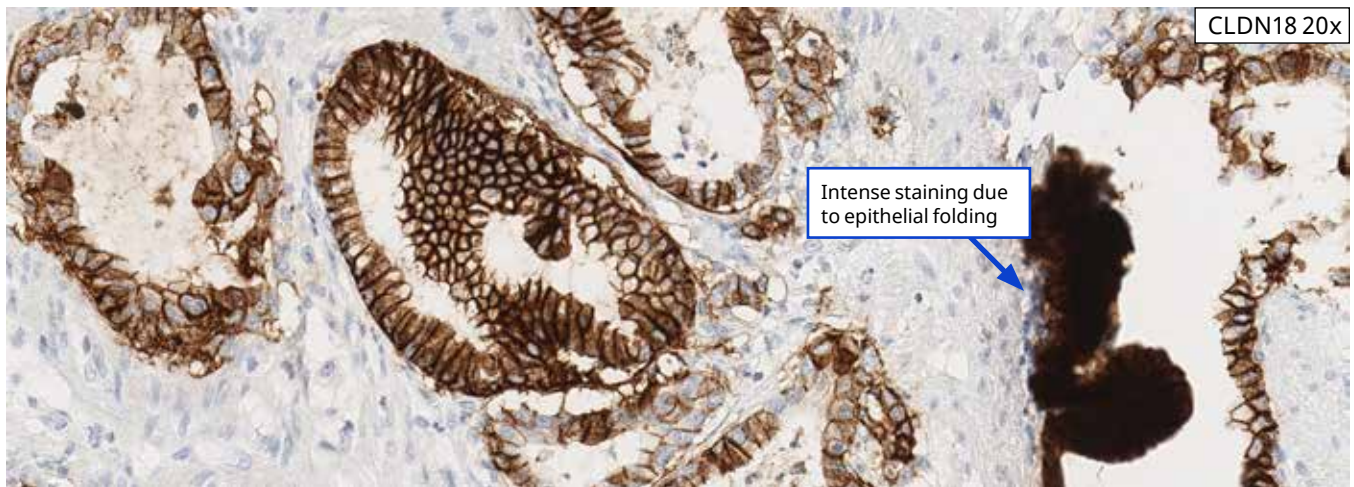
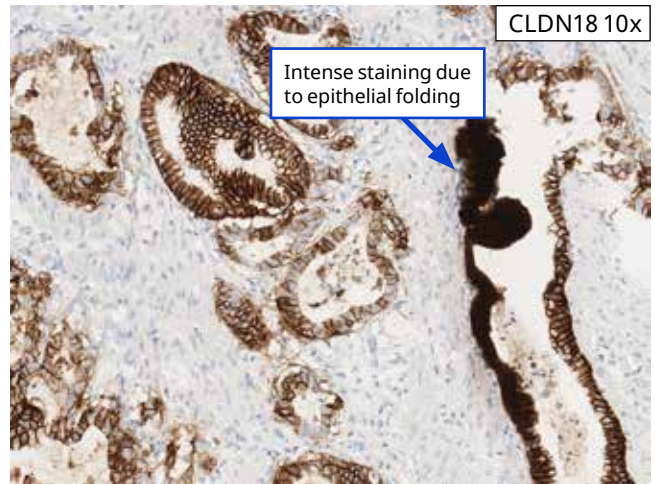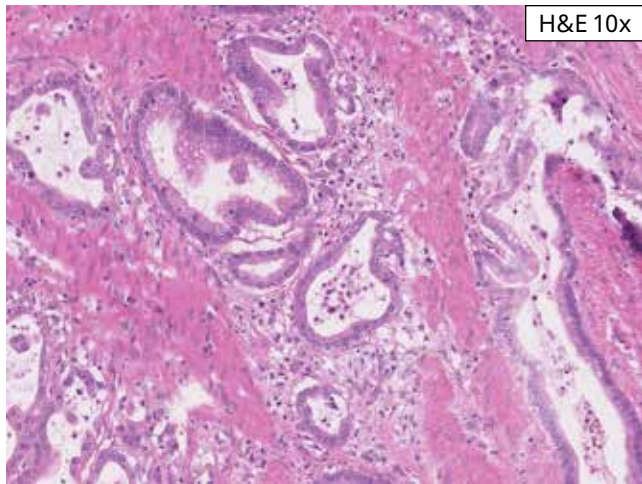
Artifact Case 4: This case shows tumor with strong CLDN18 membrane staining in 95% tumor cells. The tumor nests are within pools of mucin, which is showing mild non-specific staining. A large tissue fold is present, resulting in the overlapping of tumor tissue. This may cause the CLDN18 staining to appear stronger. For this reason, tumor within a tissue fold is not scored.



Artifact Case 5: Only viable tumor is considered as total number of tumor cells. Tumor cell staining within areas of necrosis or within intraluminal necrotic debris is excluded. The case above shows tumor cells in association with intraluminal debris in a large gland. These tumor cells are NOT scored or included toward percent positive tumor cells. Overall, the tissue section in this case shows 30% moderate to strong tumor cell staining and is negative for CLDN18 IHC status.



Artifact Case 6: NRC on the right shows the parietal cells with cytoplasmic bluish. This is occasionally seen on the NRC slide and if the only finding, is an acceptable NRC.



Artifact Case 7: The upper left H&E image shows gastric adenocarcinoma with some intraluminal necrotic debris. The CLDN18-stained tissue section on the right shows largely strong basolateral/lateral staining in 50% of tumor cells and non-specific staining of luminal debris. The gland on the far right shows a focus of apparent intensely staining malignant epithelium due to folding. It is difficult to discern true membrane staining at higher magnification (bottom image). Therefore, this focal area of intense staining would not be scored and would not count toward percent positive tumor. This case is negative for CLDN18 IHC status.

Impact of Pre-Analytical Conditions on VENTANA CLDN18 (43-14A) RxDx Assay

The recommended fixative is 10% NBF for 6-48 hours and outlined in box with blue border.

†Other acceptable fixative and fixation times include Alcoholic Formalin between 6 hours and 48 hours.

*One hour and 72 hours fixation times are not recommended for this assay.

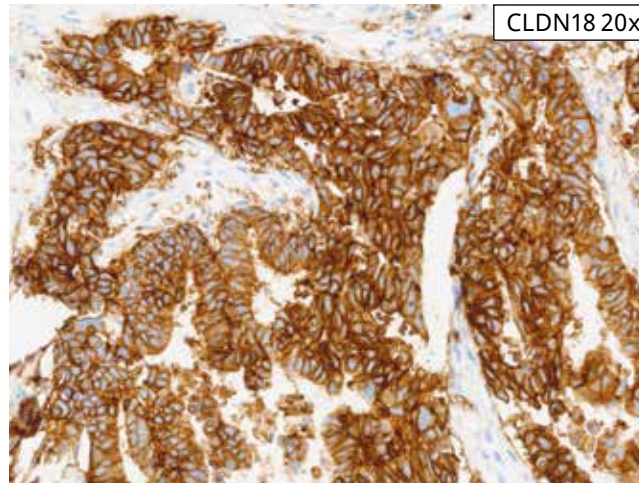
**Use of PREFER fixative (weaker staining) or Zinc formalin and alcoholic fixatives such as AFA and 95% Ethanol (high background) are not recommended.

VENTANA CLDN18 (43-14A) RxDx Assay Staining of Xenograft Resection Tissue Across Fixatives and Fixation Times						
Time Point (Hrs)	Fixative					
	10% NBF	Alcohol Formalin†	AFA**	Zinc Formalin**	95% Ethanol**	PREFER fixative**
1*						
6						
12						
24						
48						
72*						

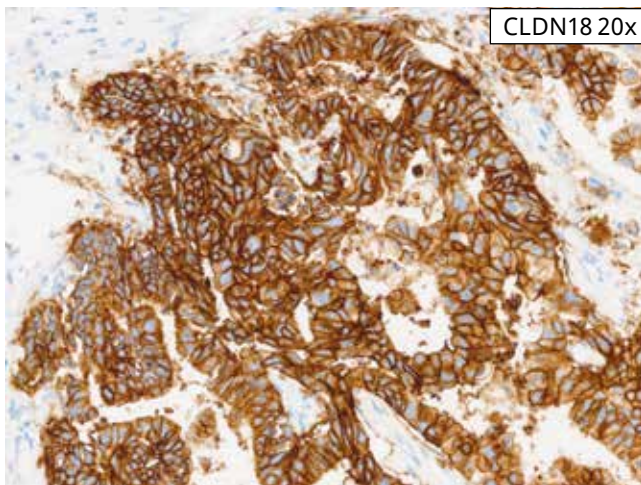
Cut Slide Stability

Slides should be stained immediately, as antigenicity of cut tissue sections may diminish over time. If not stained immediately, slides should be desiccated and stored at room temperature. Because environmental

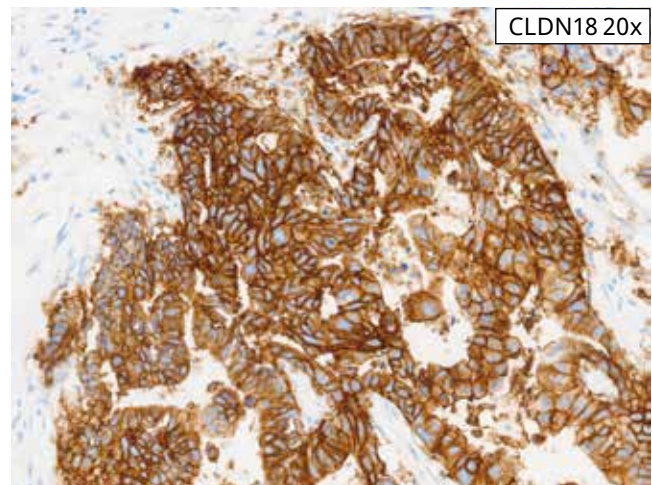
factors are known to affect antigen stability on cut slides, laboratories should validate cut slides stability within their own environment when storing beyond 45 days.



Cut Slide Stability Case 1 (Day 0, Reference Slide): Shows freshly sectioned gastric adenocarcinoma including the GEJ resection tissue stained with the VENTANA CLDN18 (43-14A) RxDx Assay.



Cut Slide Stability Case 1 (Day 45, 5°C): The tissue section shows slide stored at 5°C prior to staining with the VENTANA CLDN18 (43-14A) RxDx Assay on Day 45.



Cut Slide Stability Case 1 (Day 45, 30°C): The tissue section shows slide stored at ambient temperature (room temperature, 30°C) prior to staining with the VENTANA CLDN18 (43-14A) RxDx Assay on Day 45.

Note that there is absence of diminished staining in the slides stained on Day 45 (lower panels) compared to the reference slide stained on Day 0 (top panel).

References

1. Sung H, Ferlay J, Siegel R, Dikshit R, Laversanne M, Soerjomataram I, Ahmedin J, et al. Global cancer statistics 2020: GLOBOCAN estimates of incidence and mortality worldwide for 36 cancers in 185 countries. *CA Cancer J Clin* 2021;71:209-49.
2. Global Cancer Facts and Figures, American Cancer Society, 4th edition. 2018.
3. Ferlay J, Ervik M, Lam F, Colombet M, Mery L, Pineros M, et al (eds). WHO Cancer Today. GLOBOCAN, 2020.
4. Siegel RL, Miller KD, Fuchs HE, Jemal A. Cancer statistics, 2022. *CA Cancer J Clin* 2022; 72:7-33.
5. Hashimoto I, Oshima T. Claudins and gastric cancer: an overview. *Cancers (Basel)*. 2022;14(2):290.
6. Singh P, Toom S, Huang Y. Anti-Claudin 18.2 antibody as new targeted therapy for advanced gastric cancer. *J Hematol Oncol*. 2017;10(1):105.
7. Gunzel D, Yu A. Claudin and the modulation of tight junction permeability. *Physiol Rev*. 2013;93(2):525-69.
8. Selim JH, Shaheen S, Sheu WC, et al. Targeted and novel therapy in advanced gastric cancer. *Exp Hematol Oncol*. 2019; 8:25.

This page is blank

Revision History

Rev	Updates
A	Initial release
B	<ol style="list-style-type: none">1. Updated the Ventana logo2. Fonts updated in the entire document



Ventana Medical Systems, Inc.
1910 E. Innovation Park Drive
Tucson, AZ 85755
USA
+1 520 887 2155
+1 800 227 2155 (USA)



navifyportal.roche.com

© 2024 Ventana Medical Systems, Inc. All rights reserved.

VENTANA, BENCHMARK and OPTIVIEW are trademarks of Roche. All other product names and trademarks are the property of their respective owners.

1021576EN Rev B

2024-10-01

